

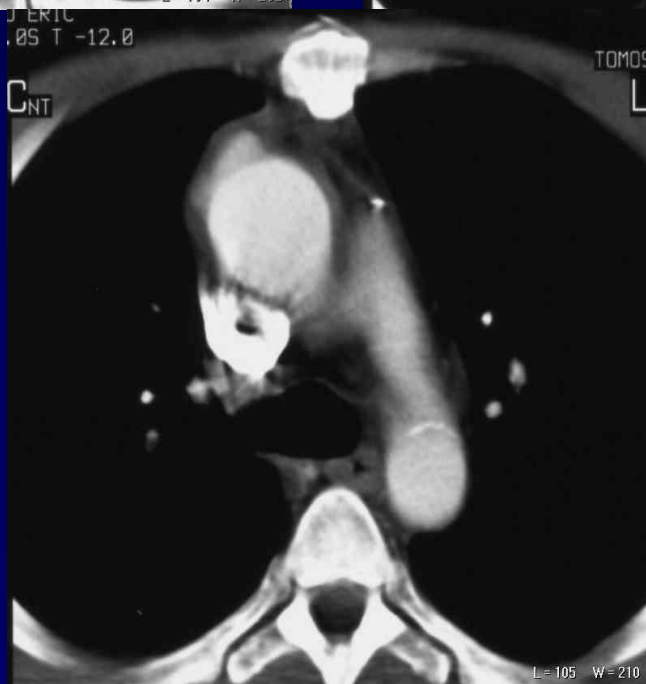
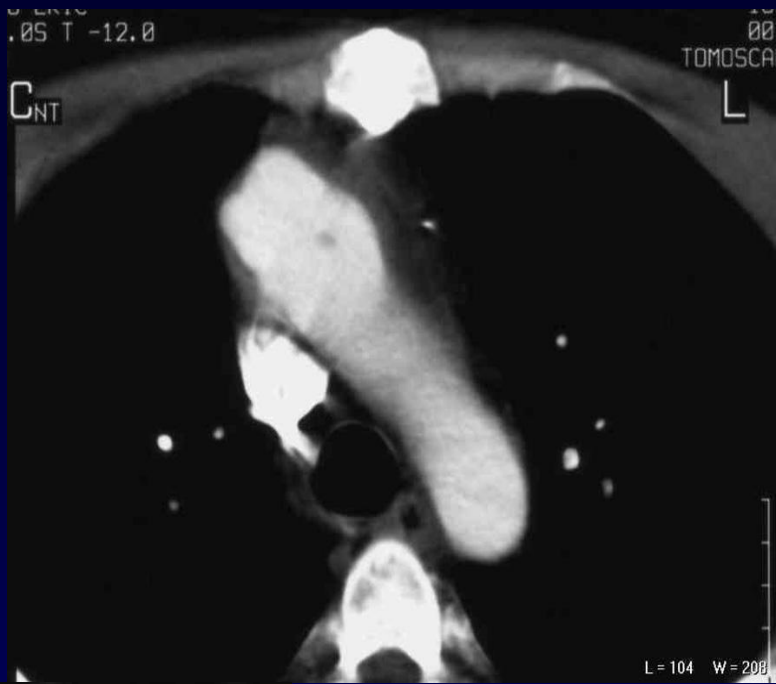
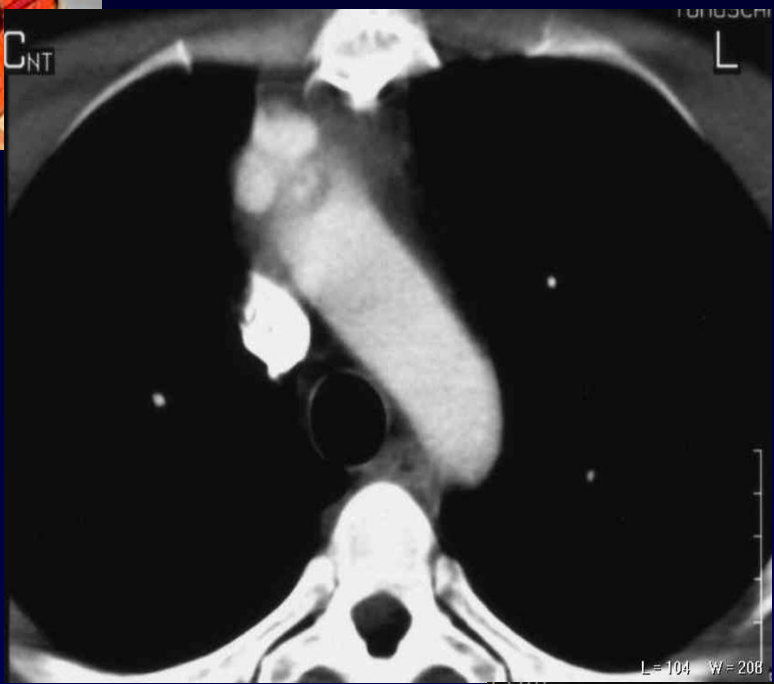


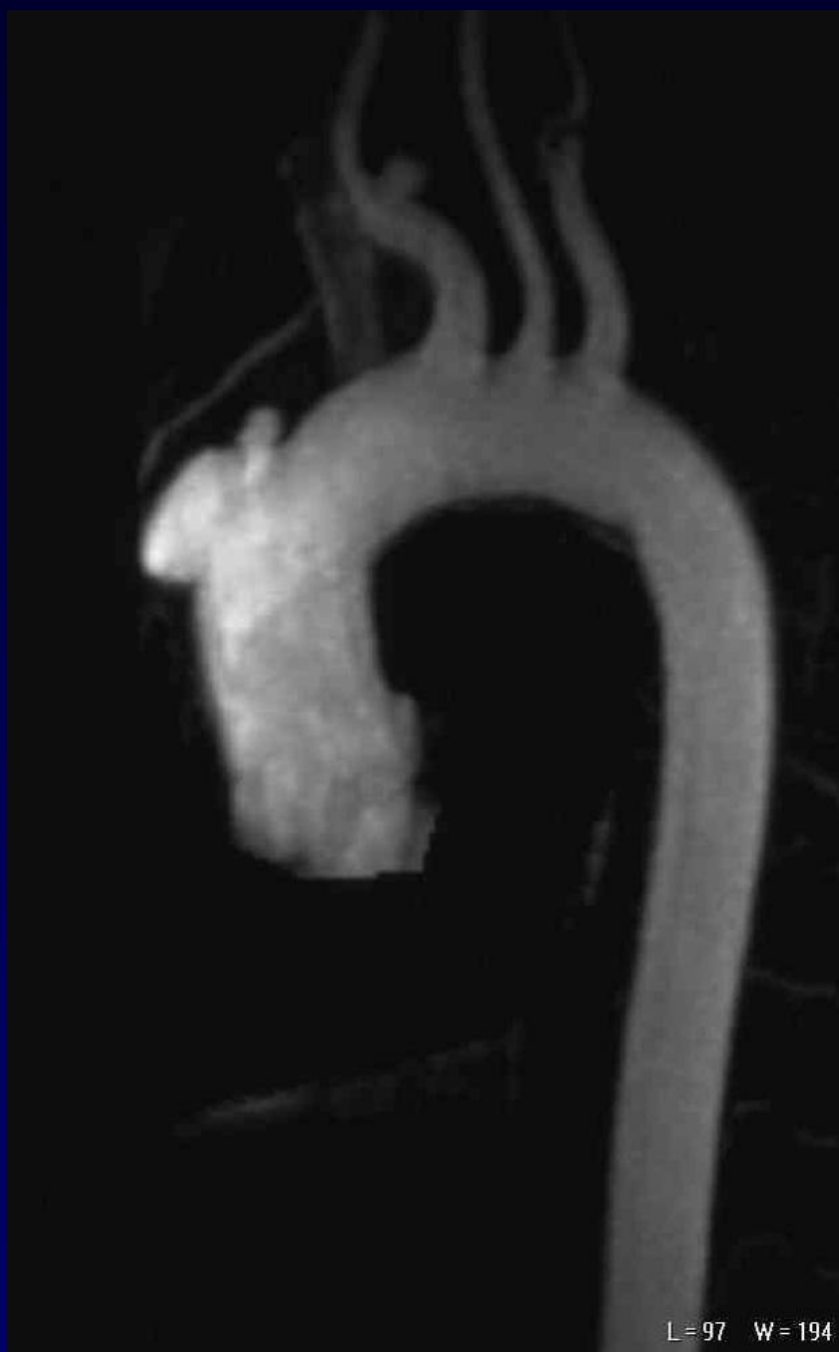
S. TROGRLIC

Homme de 37 ans

Greffe cardiaque 3 ans auparavant

Fièvre au long cours





L=97 W=194



Diagnostic ?



Pseudo-anévrisme post-opératoire sur suture