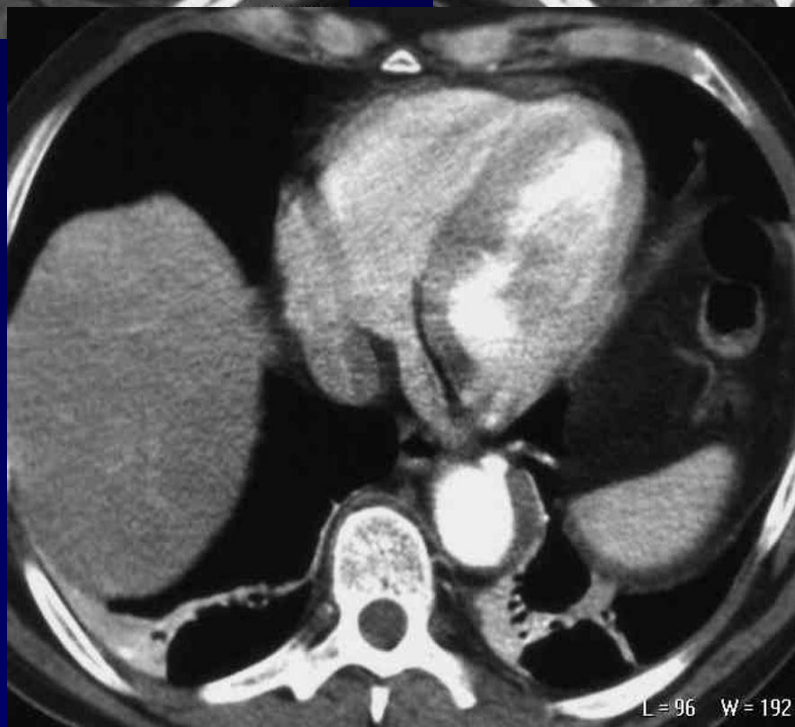
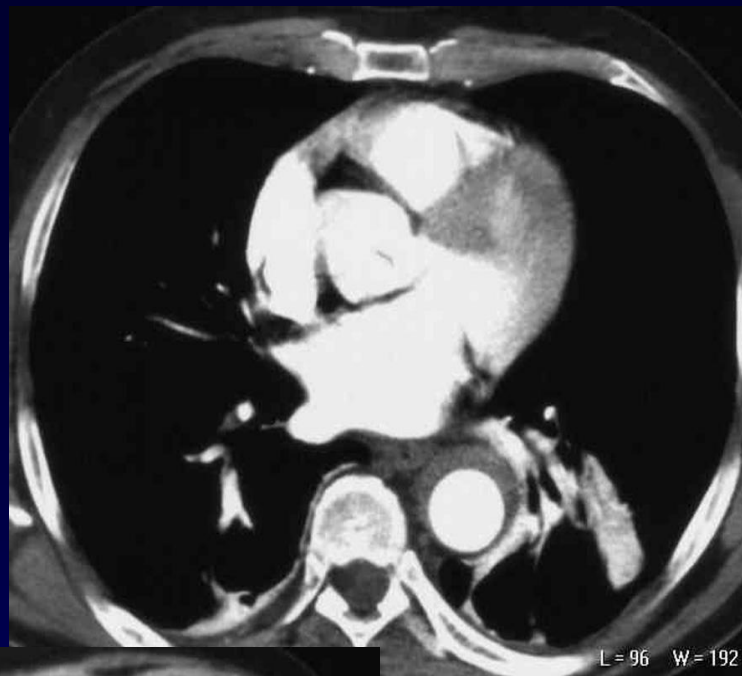
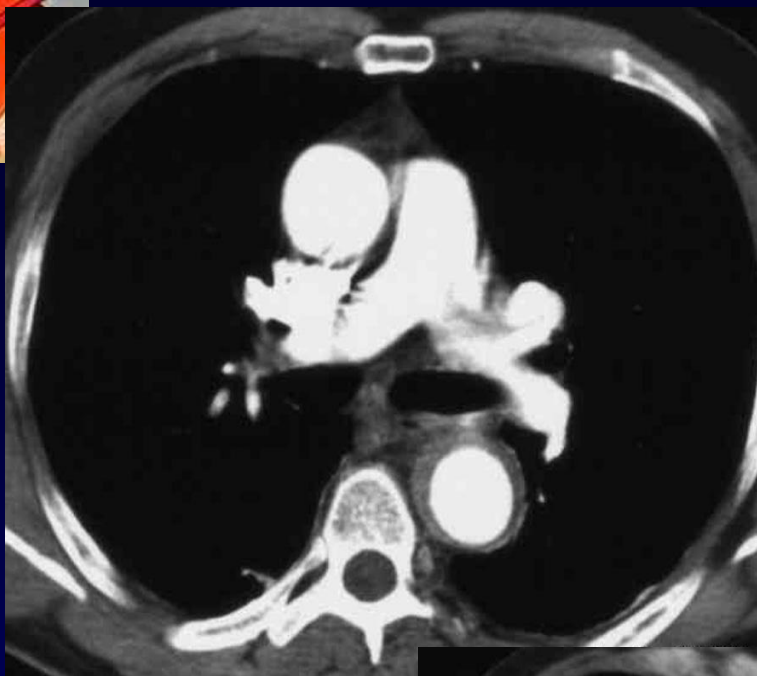
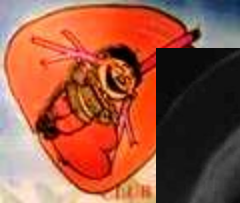


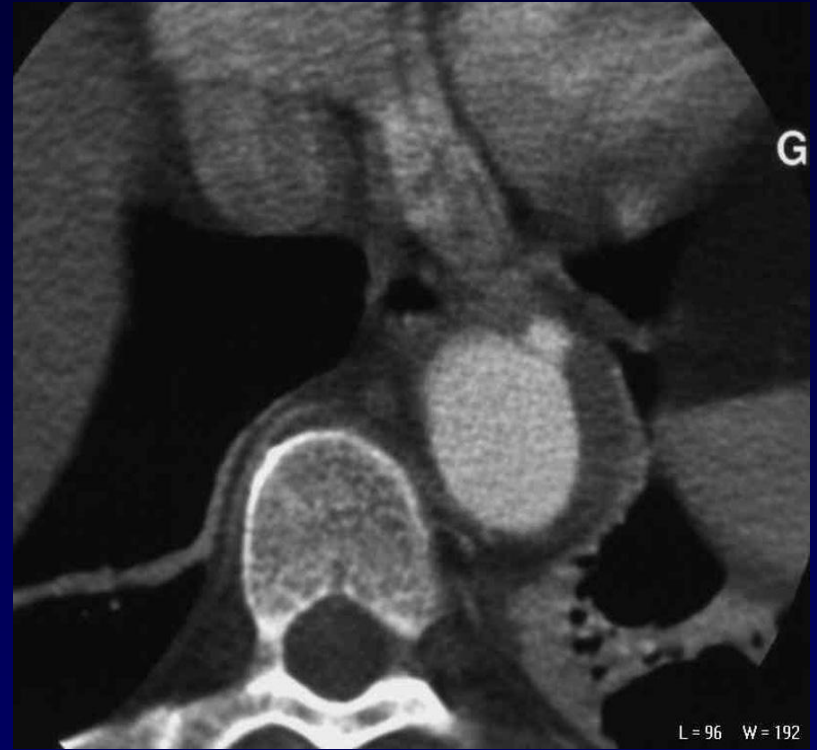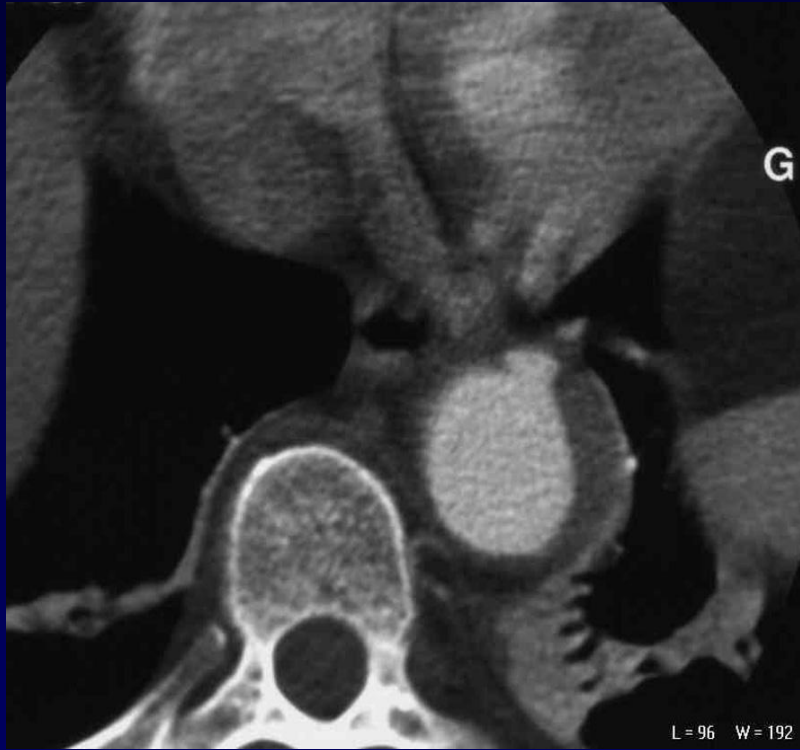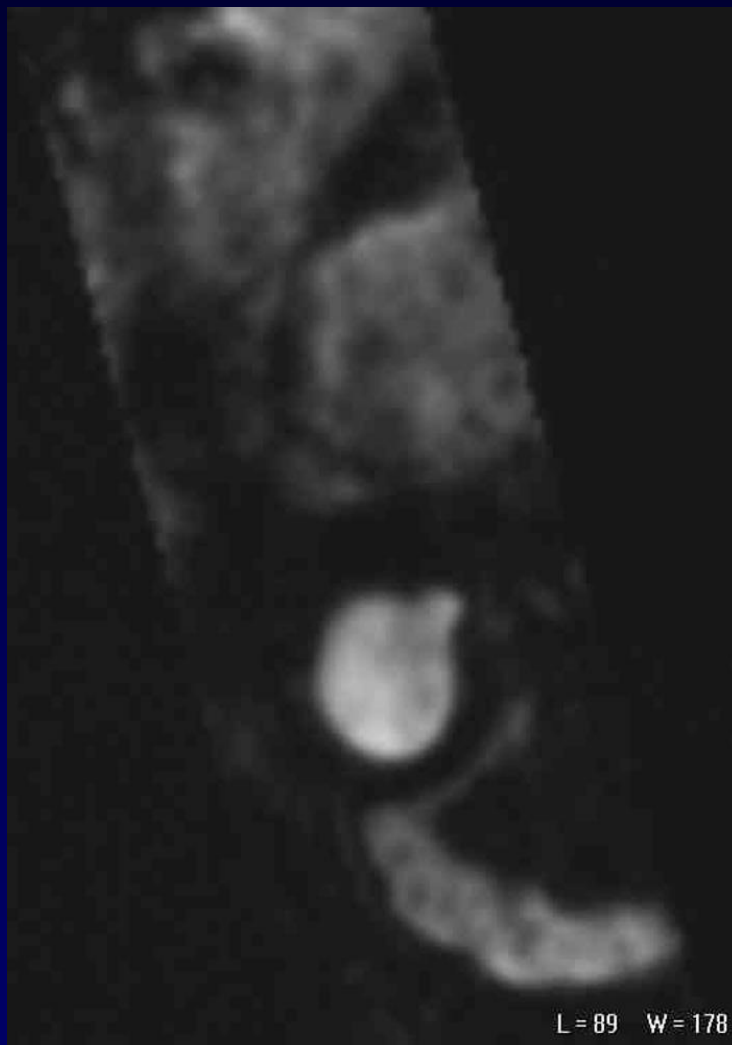
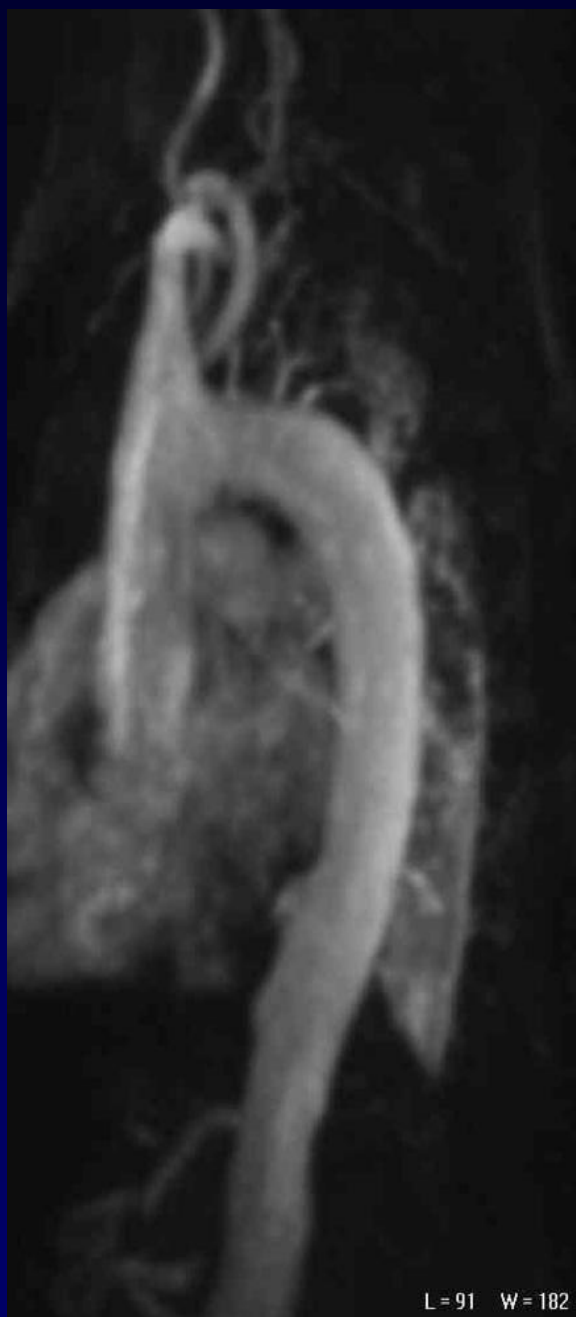
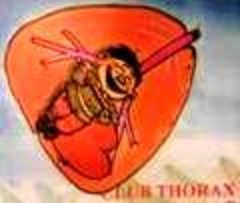D. JEANBOURQUIN

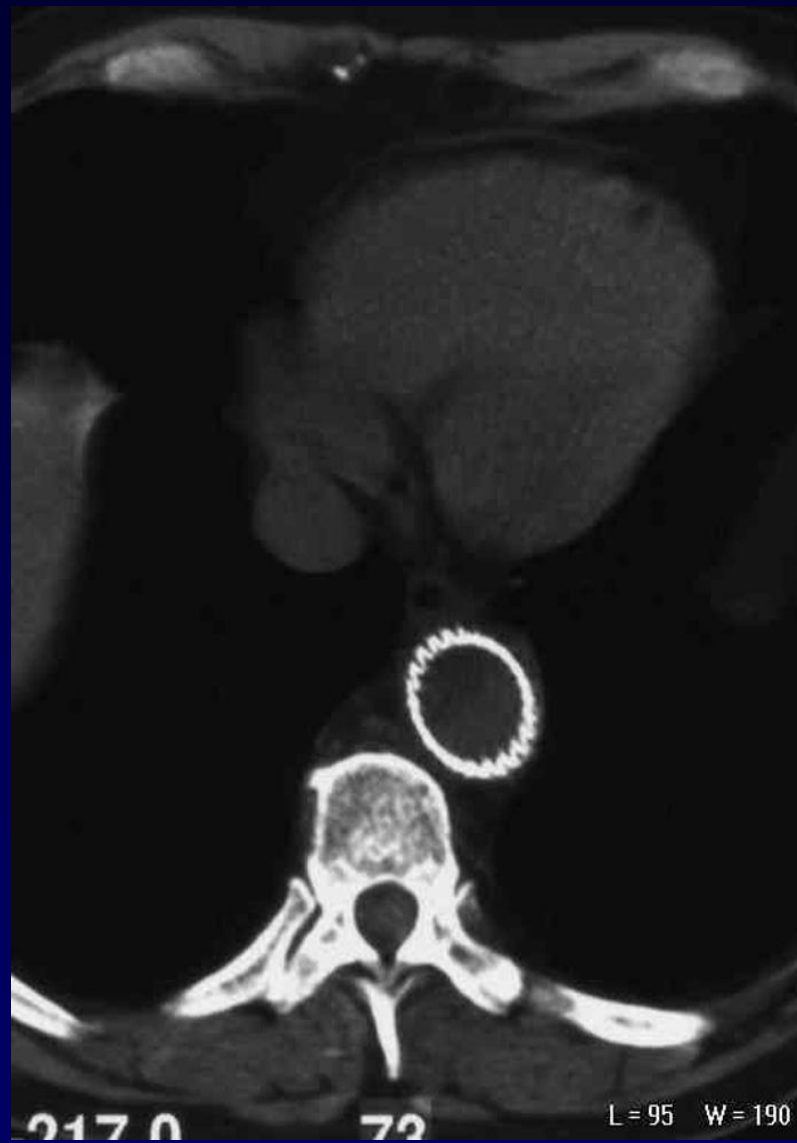
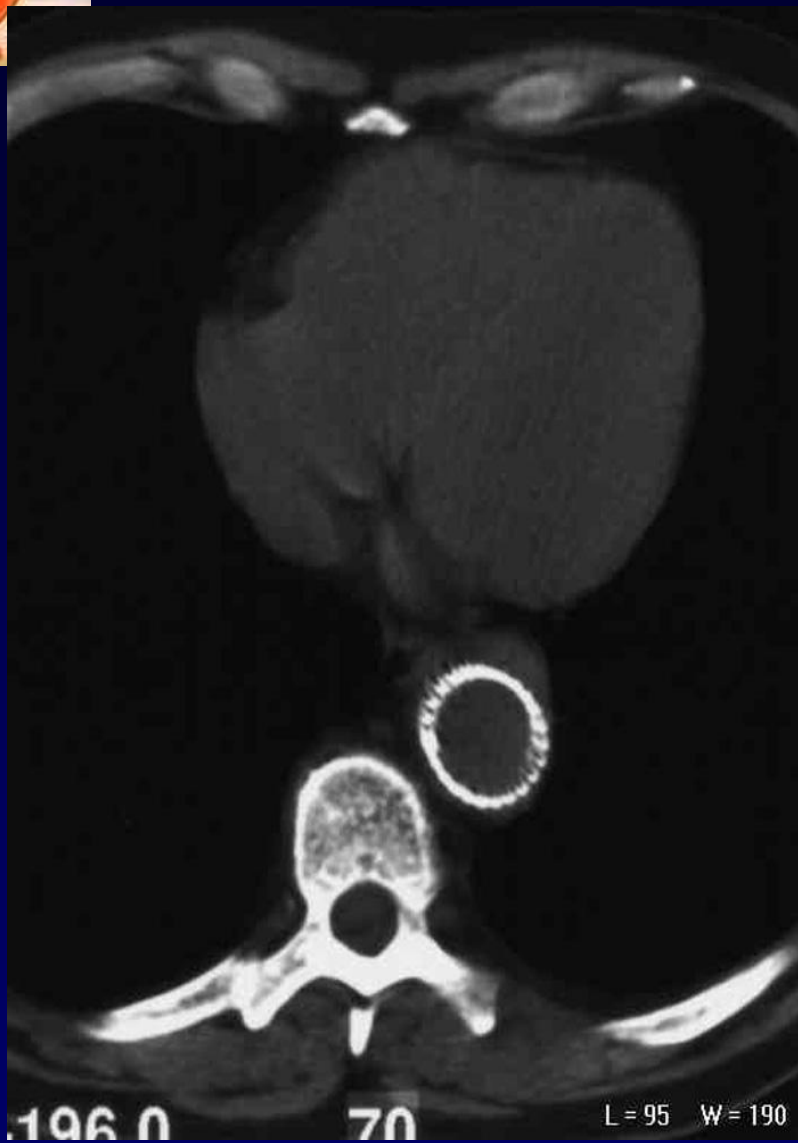
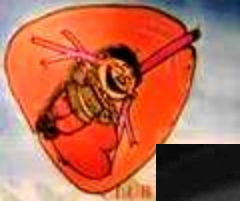Homme de 57 ans

Douleurs épigastriques



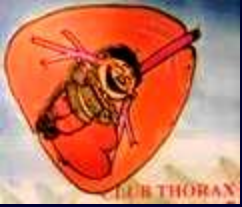







Diagnostic ?



HEMATOME DISSEQUANT DE L'AORTE SUR ULCERE DE LA PAROI ANTERIEURE

Traitement par endoprothèse devant l'augmentation de
volume de l'ulcération pariétale au cours de la
surveillance