

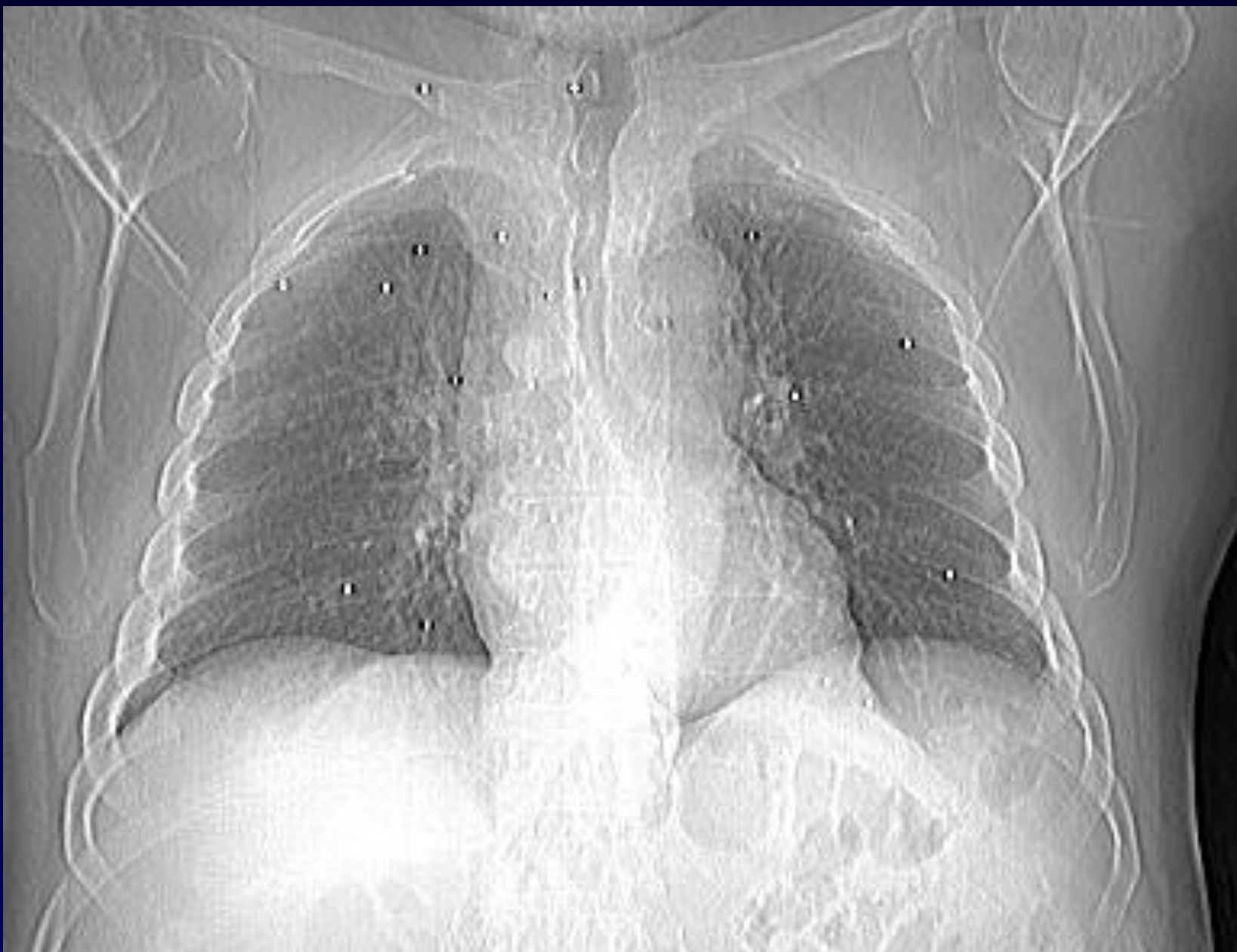


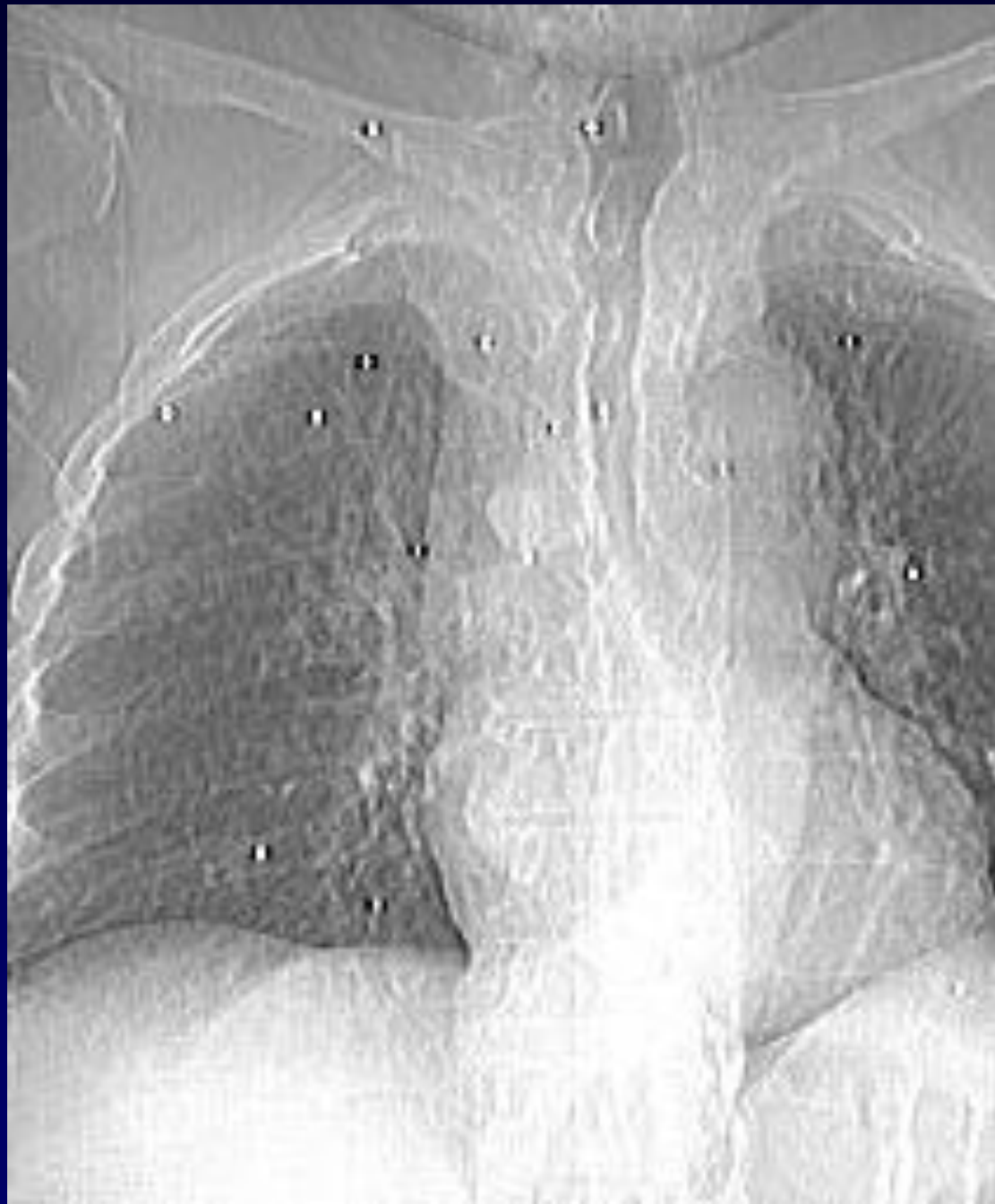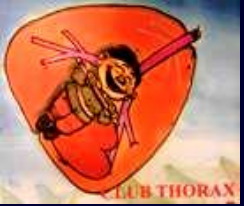Pierre FAJADET

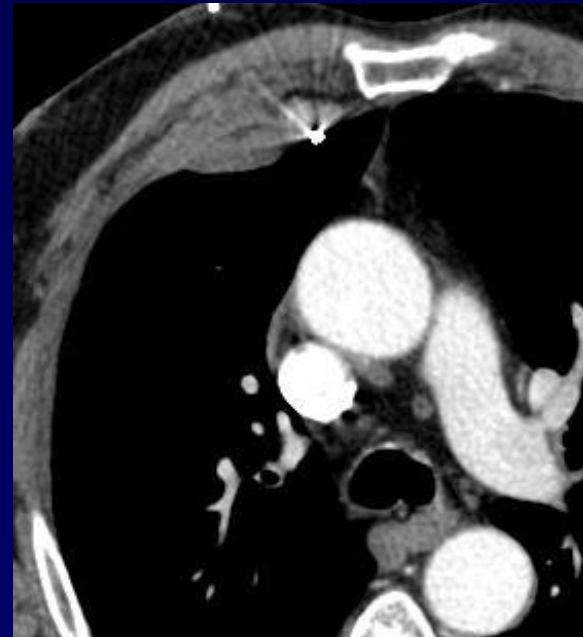
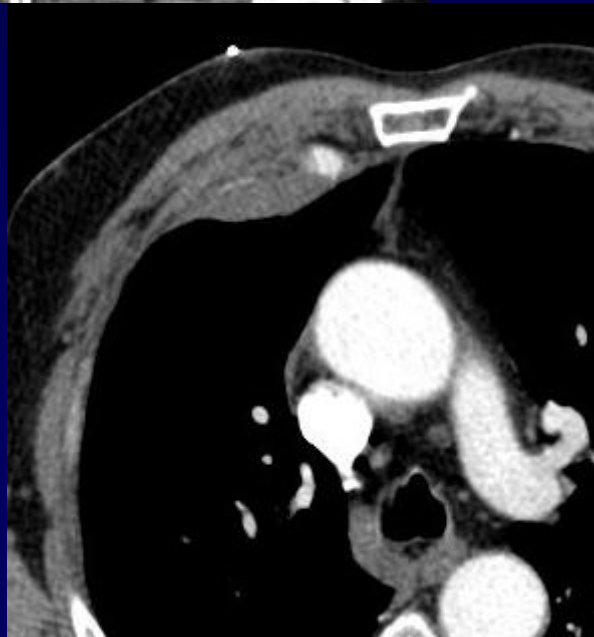
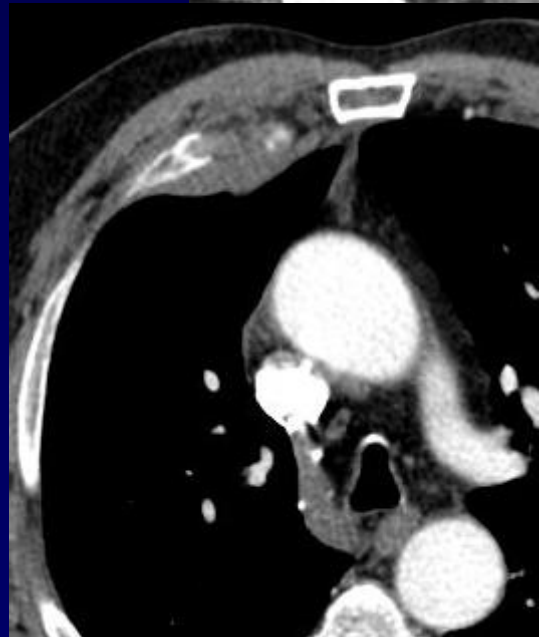
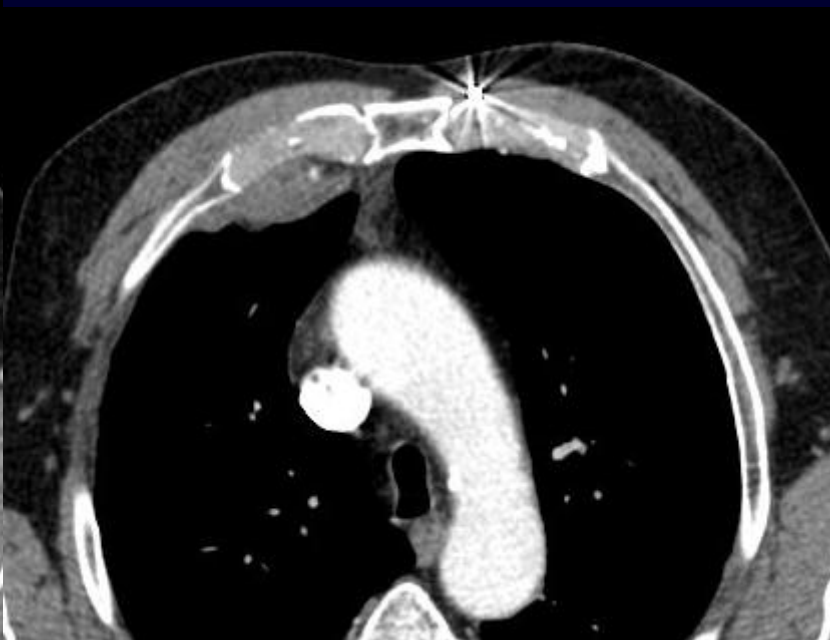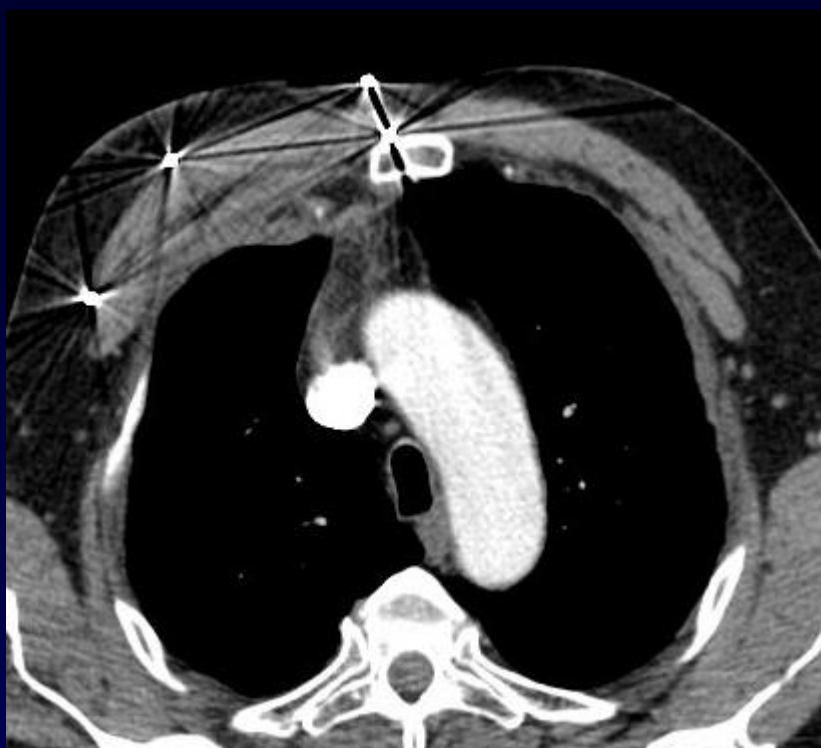Homme de 70 ans

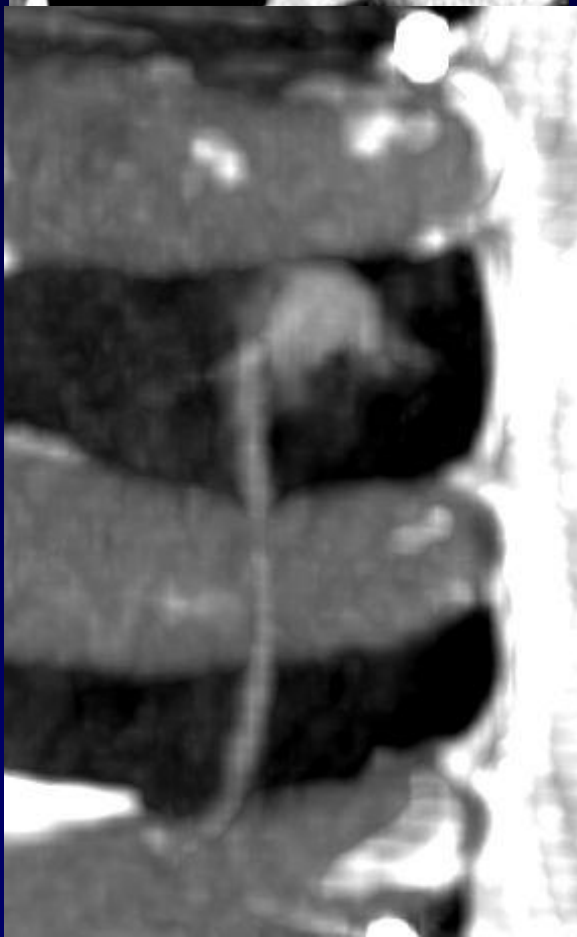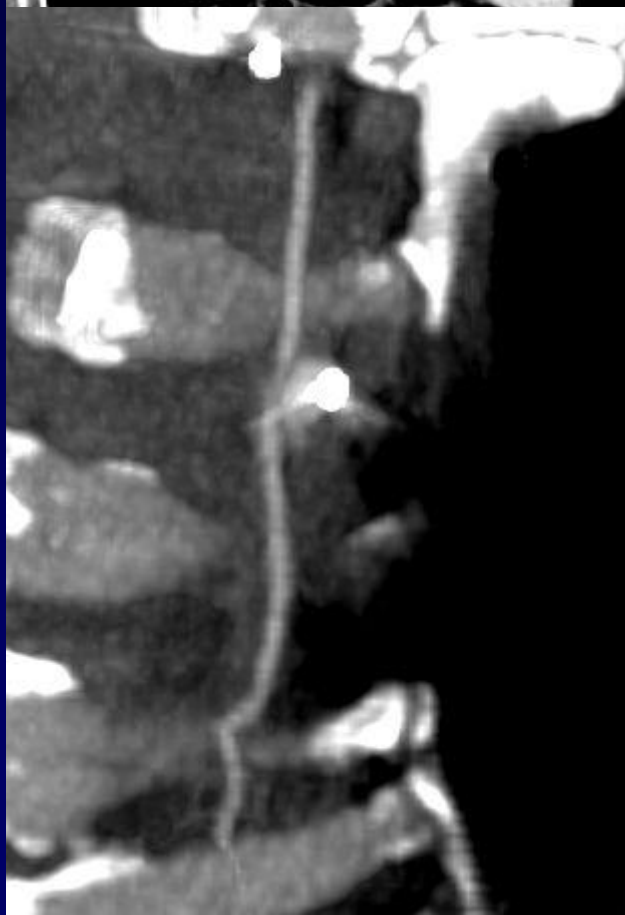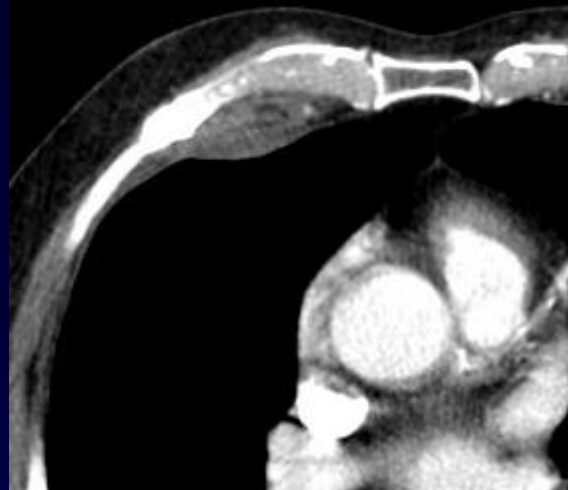
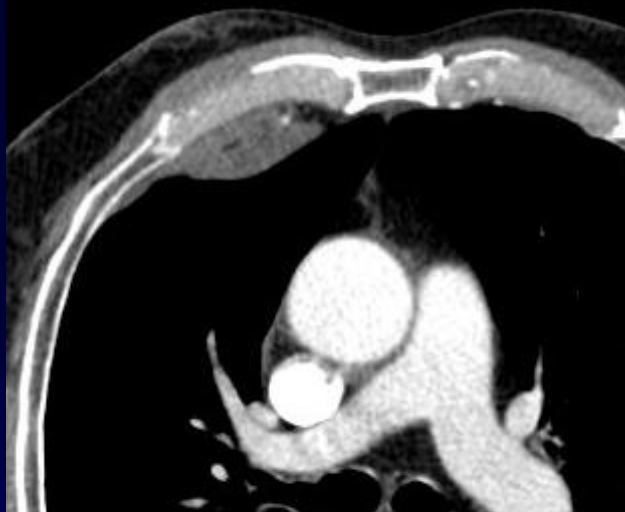
Cl: accident de chasse

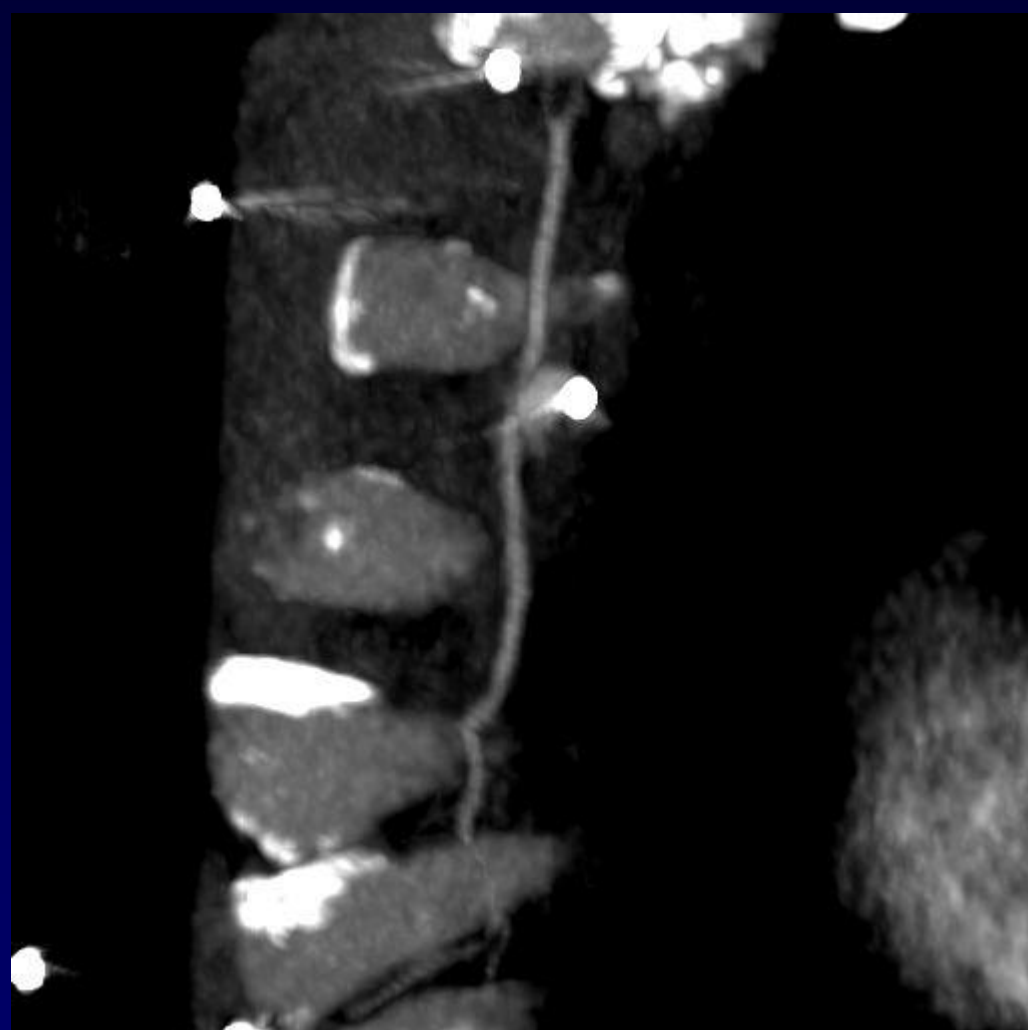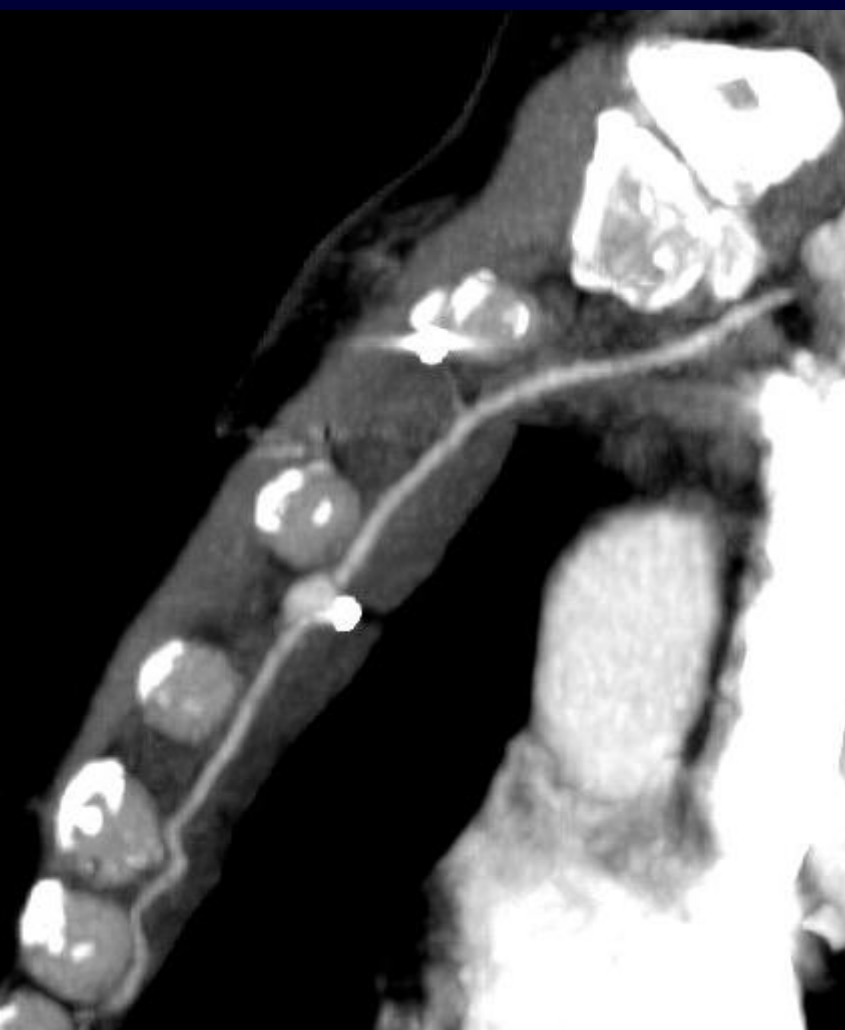cartouche à plombs de 9 à « dispersion »





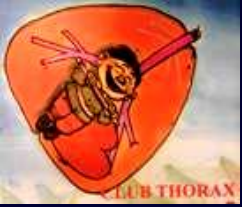







Diagnostic ?

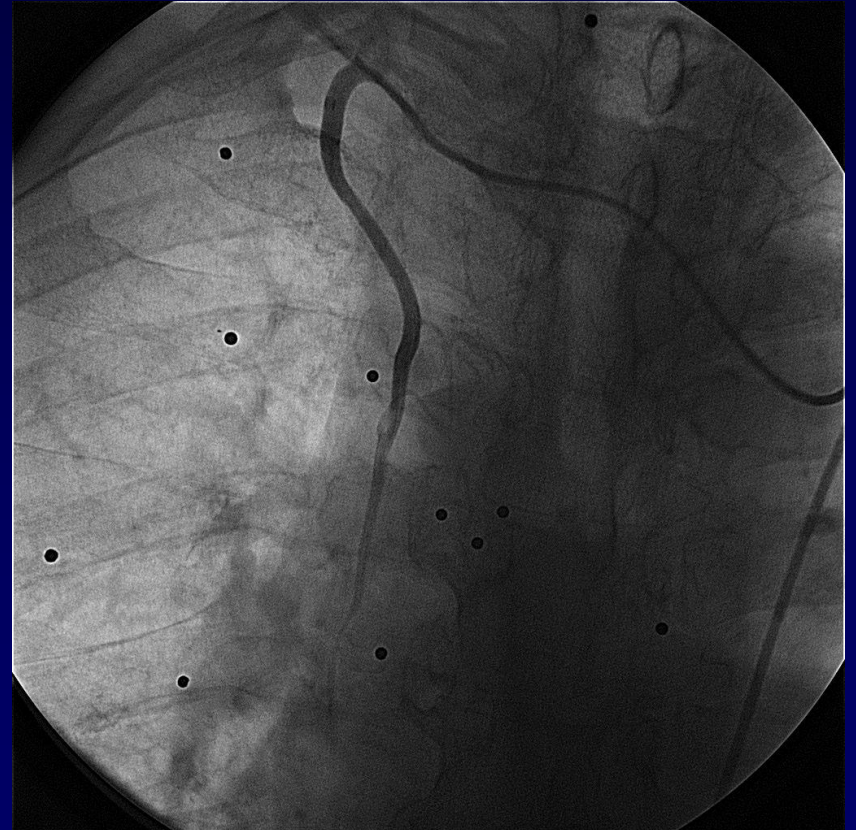
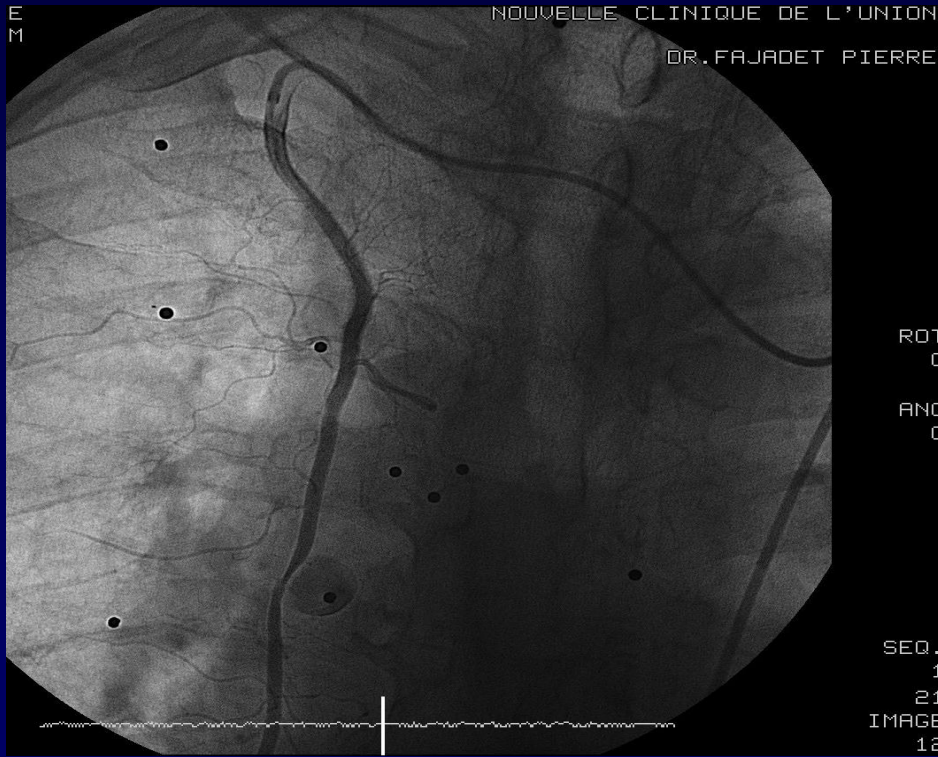


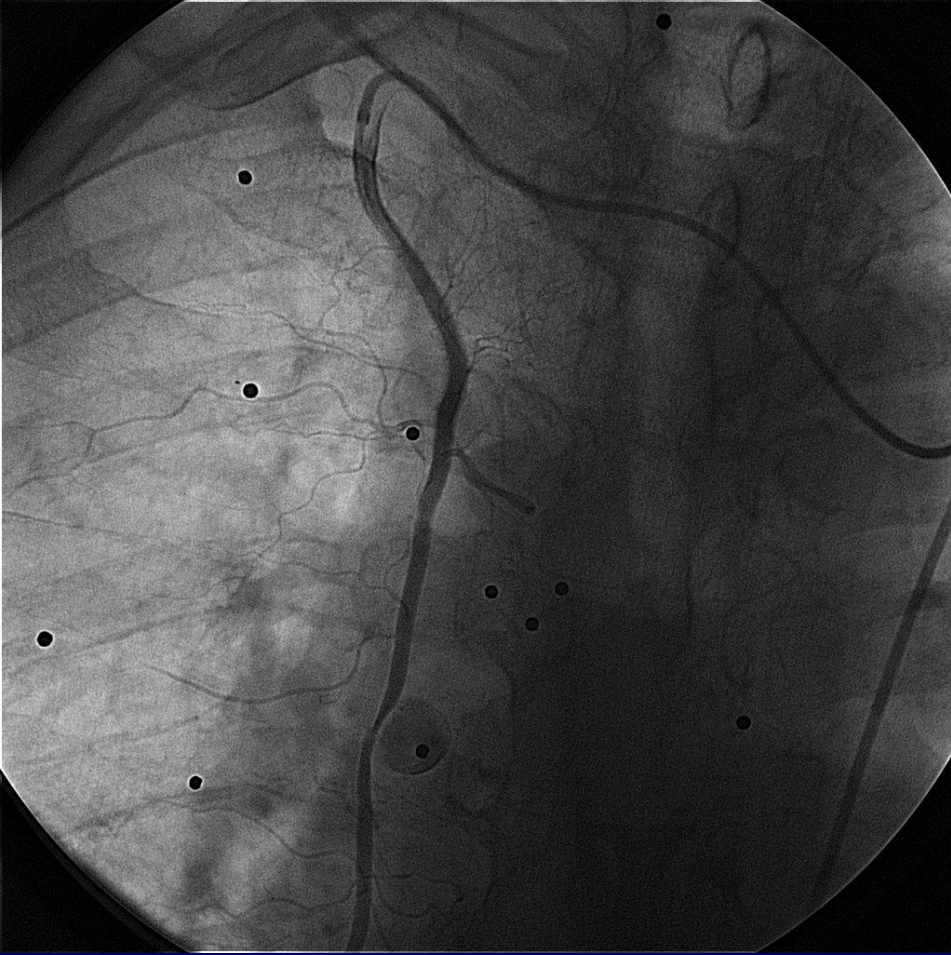
Diagnostic

**Faux anévrysme par plomb de l'artère
thoracique interne droite**

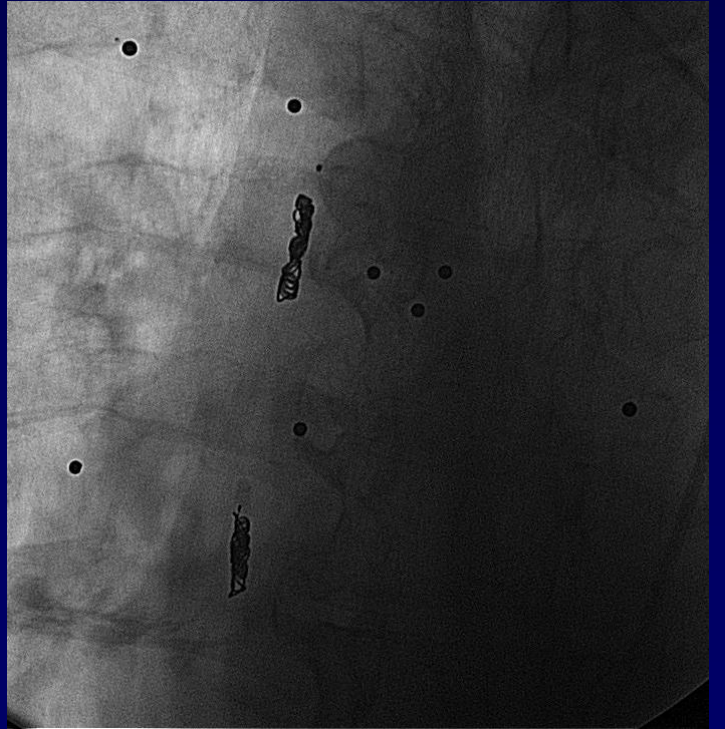
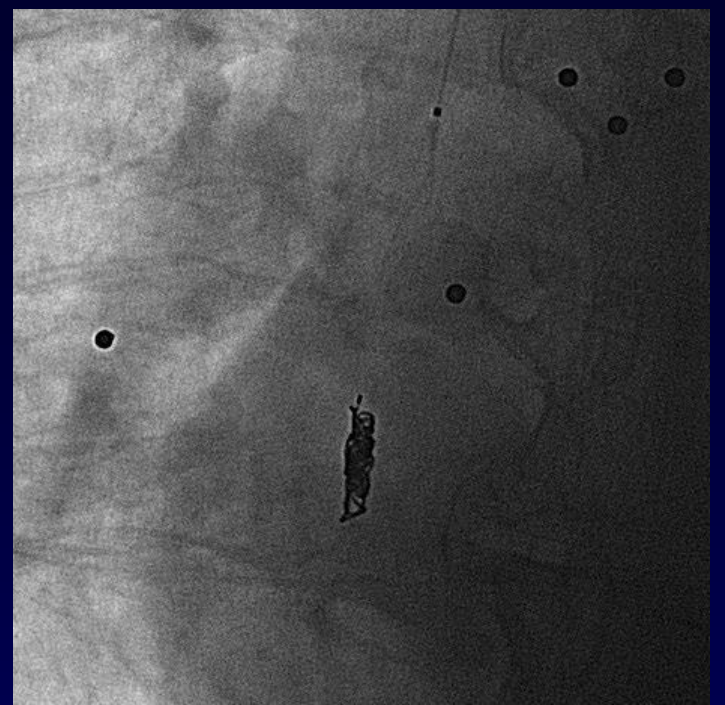

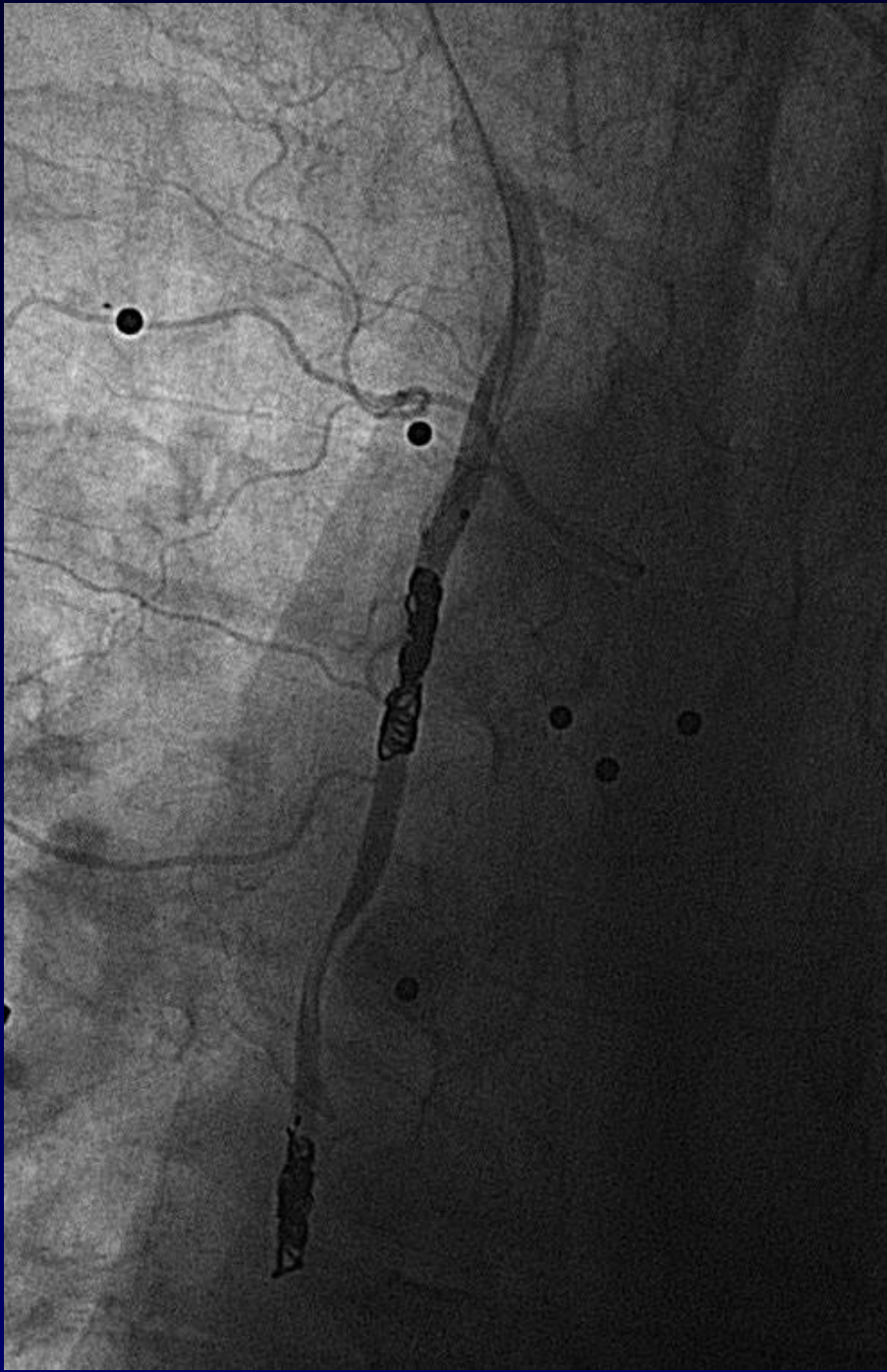CAT





C







Evolution-Discussion-Point fort

Rare

Vaso-occlusion prenant en « sandwich » le faux
anévrisme : back flow +++

Cathéter de mammaire interne- microcath.- coils
« recapturables »