

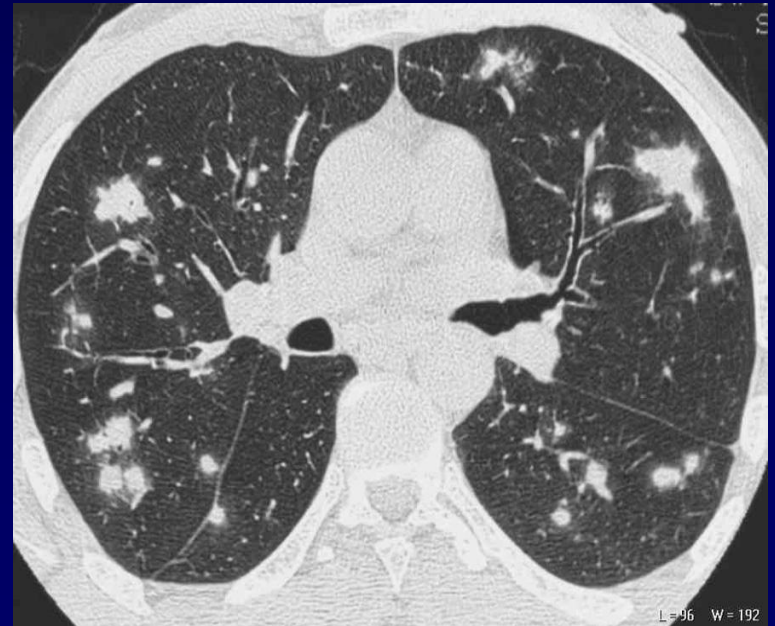
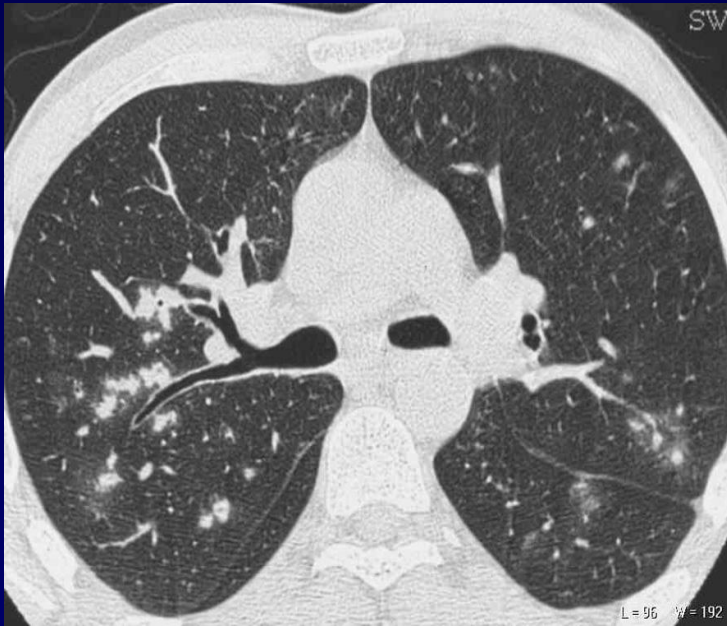
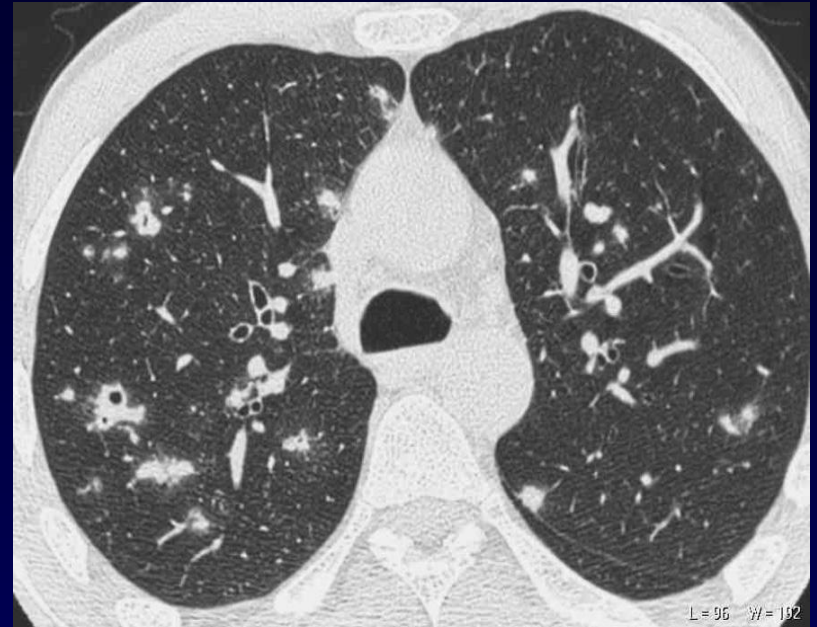
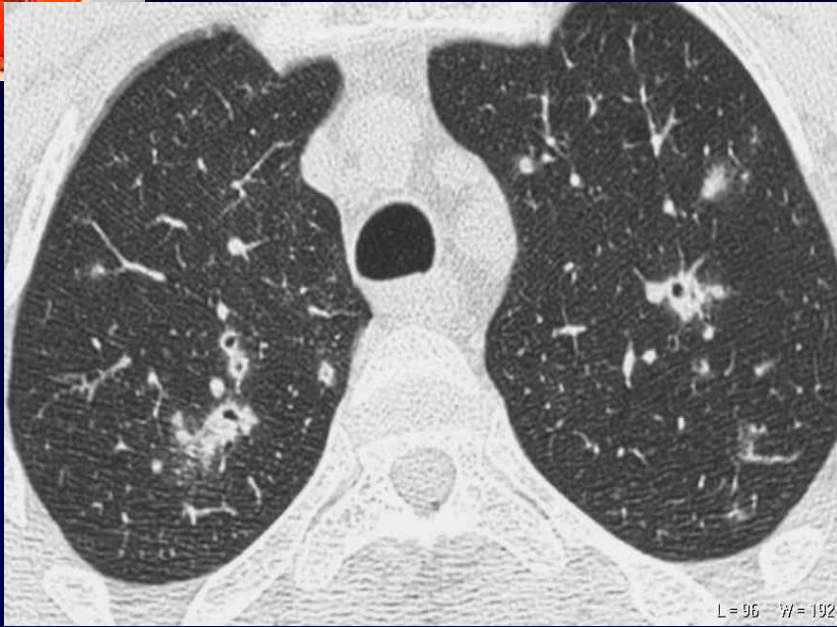

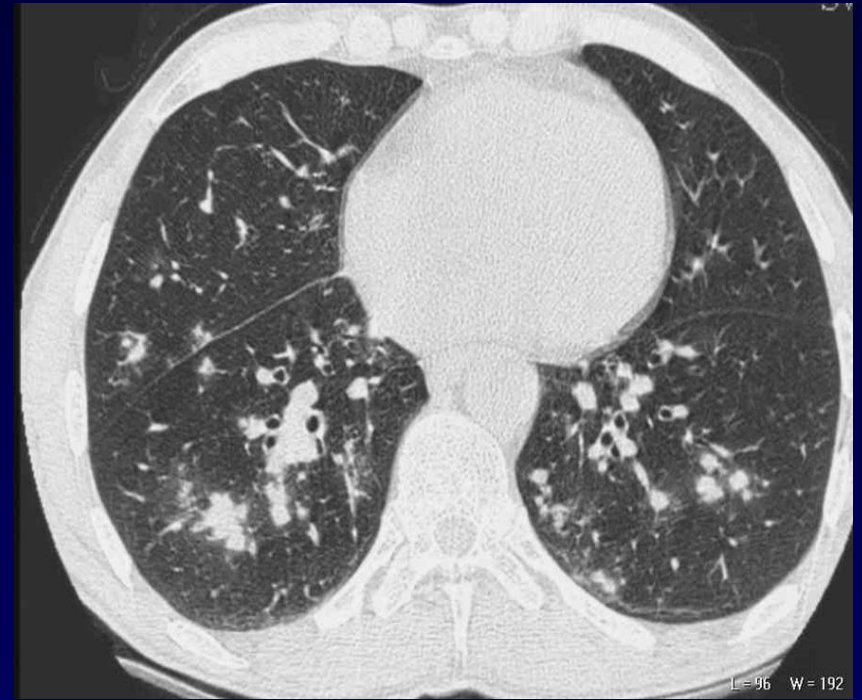
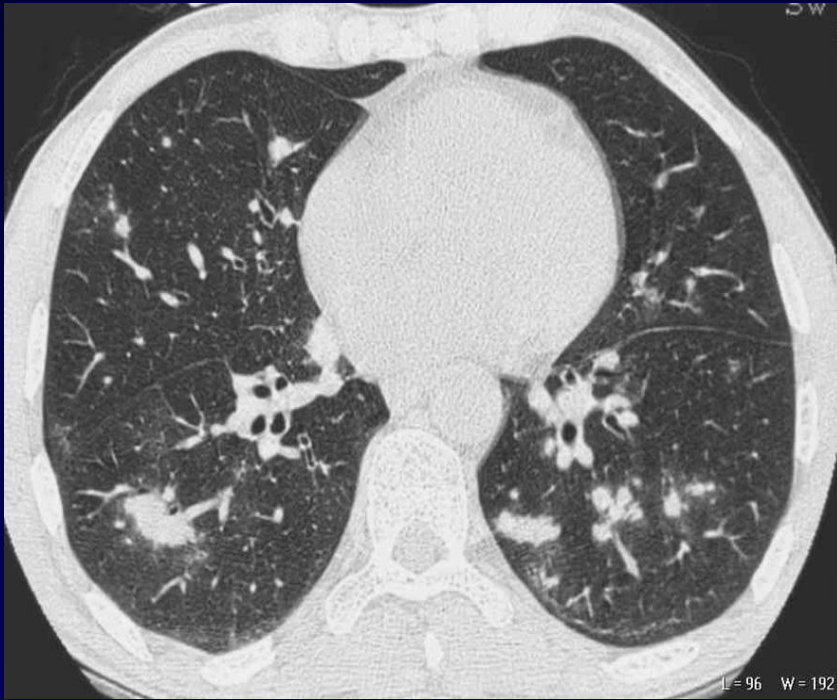
M. ABEHSERA

Homme de 55 ans

Patient présentant un SIDA

Scanner de mars 1999

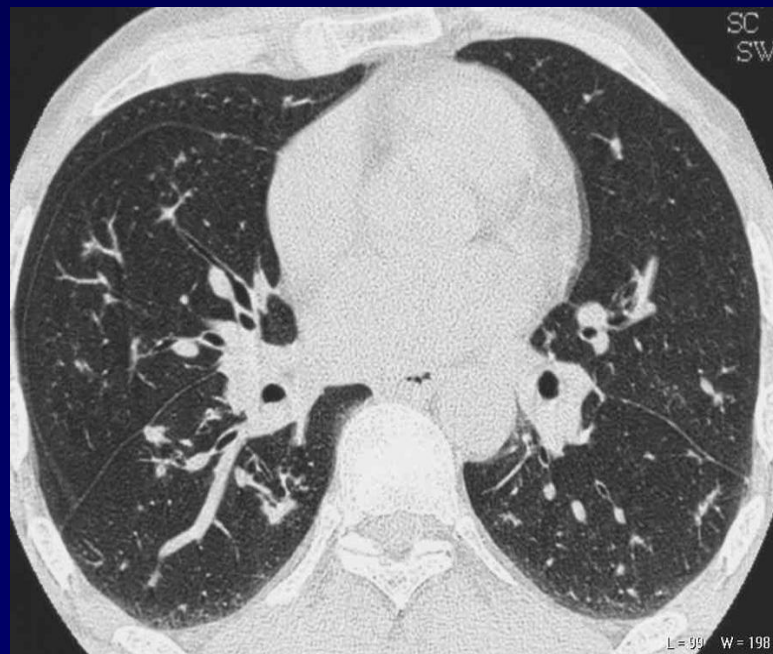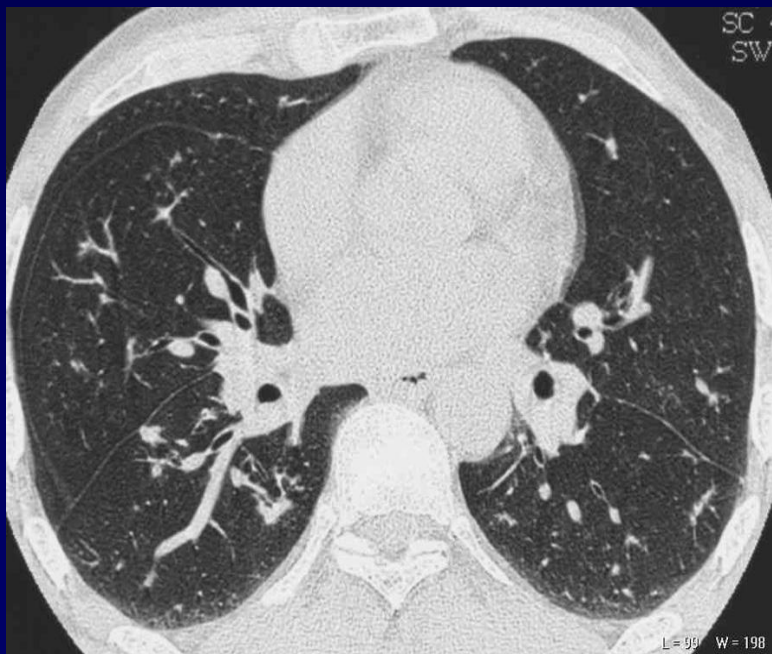
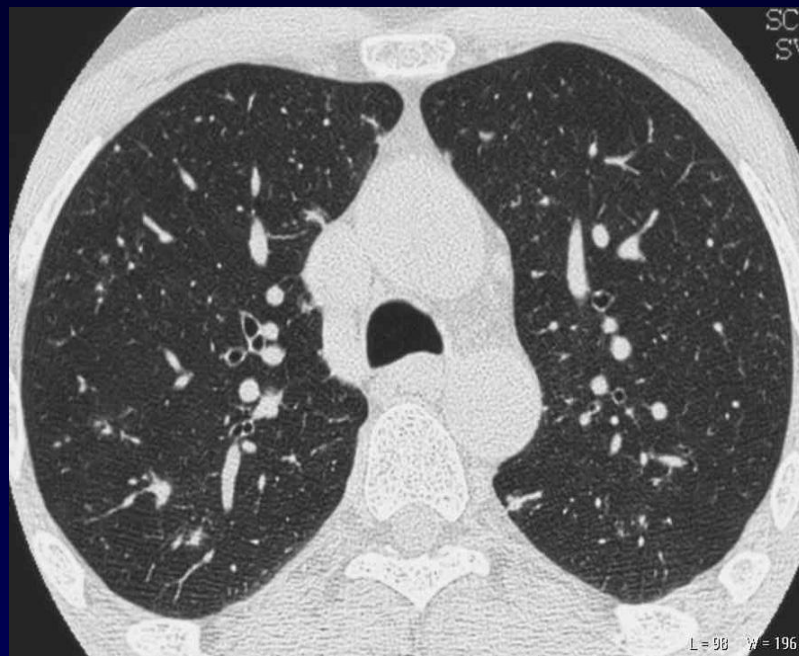

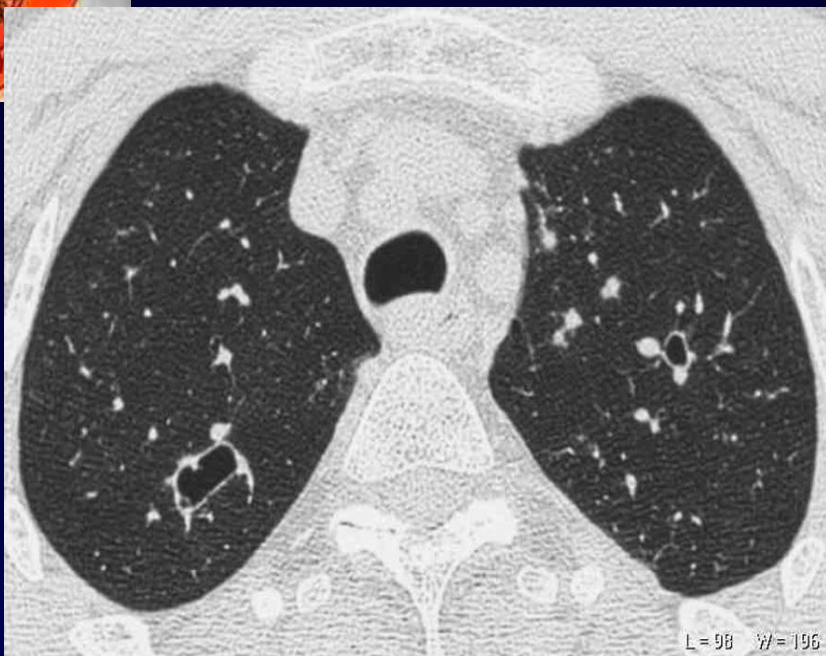


Scanner de mars 1999



Scanner d'août 1999





Diagnostic ?



MYCOBACTERIES ATYPIQUES

A XENOPI