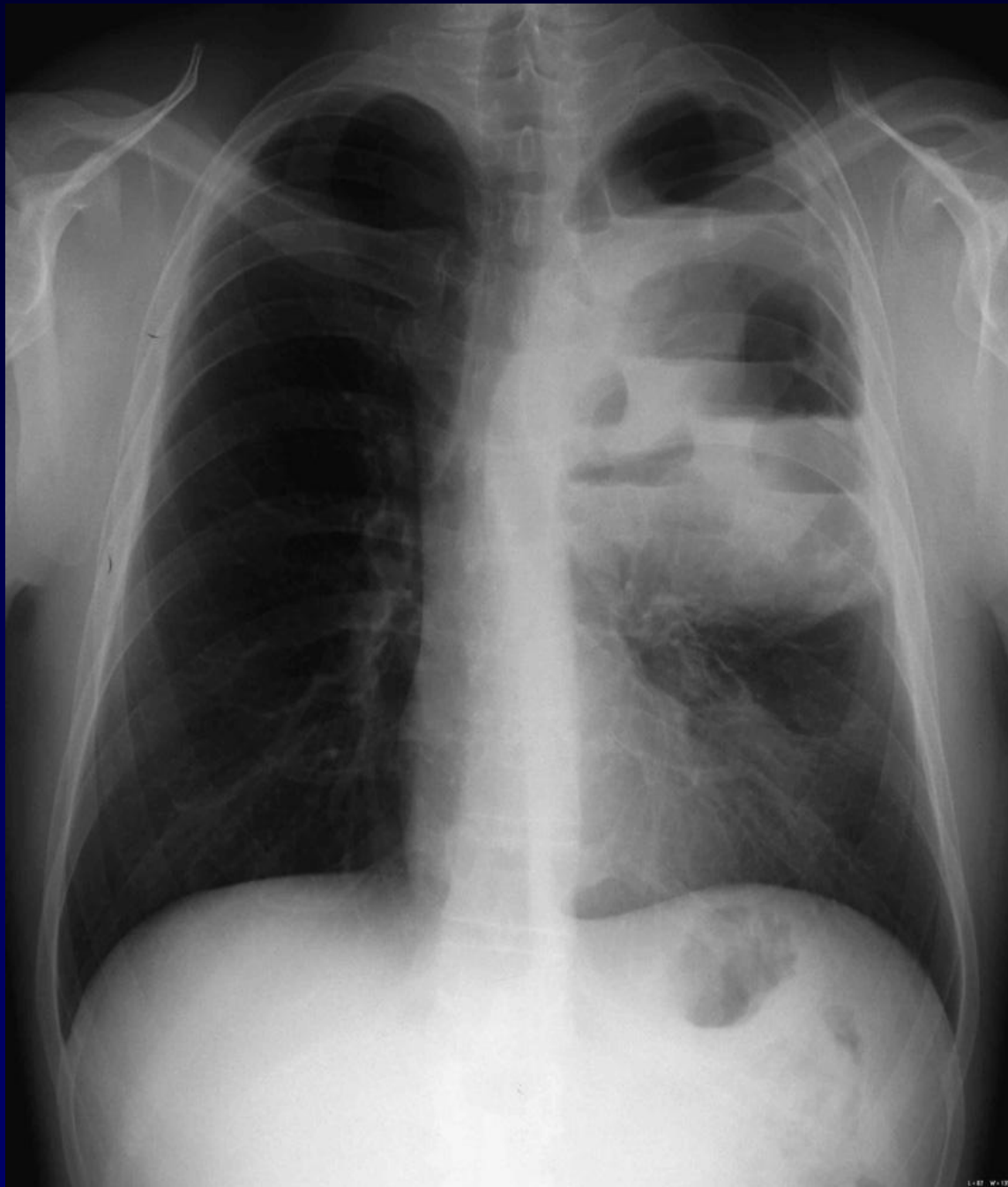

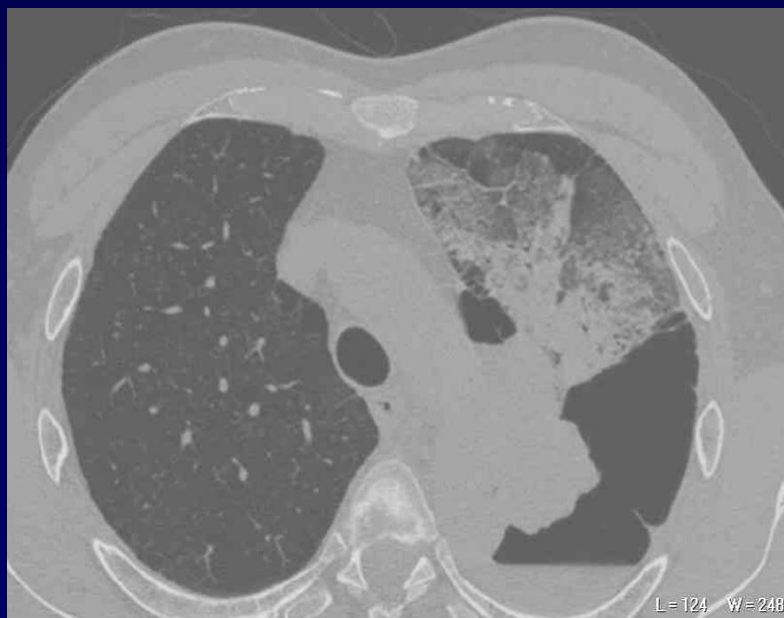

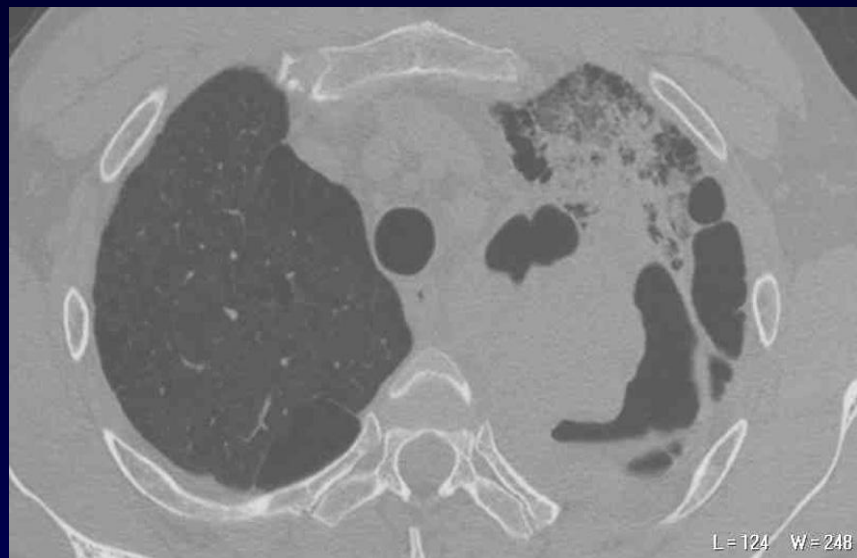
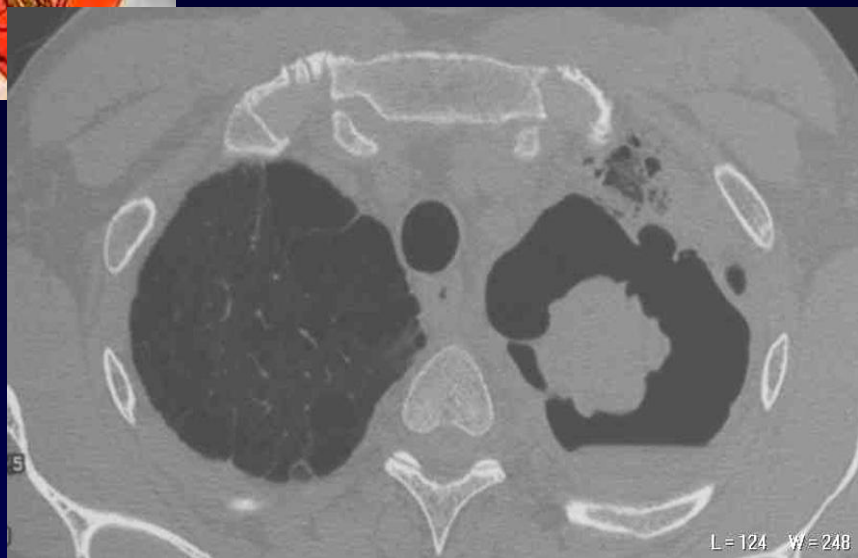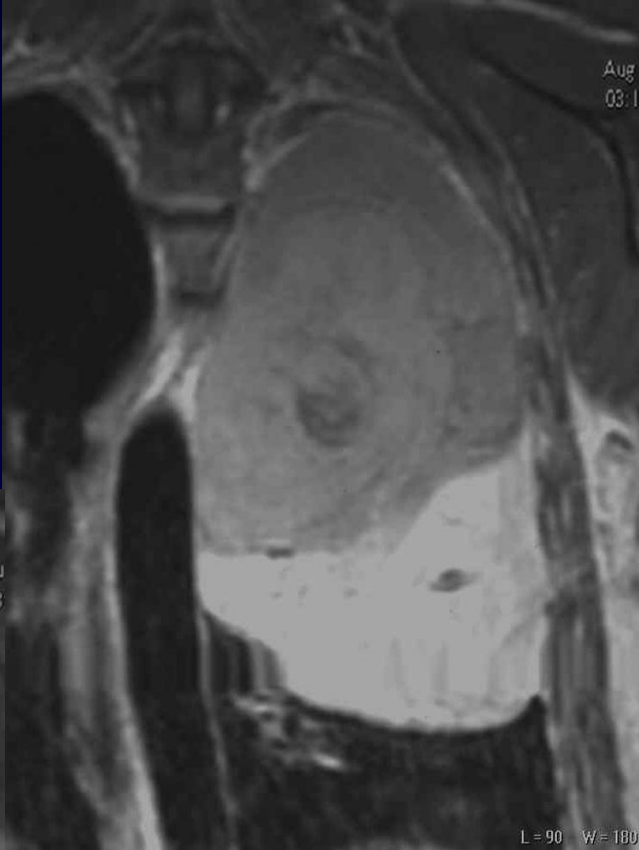
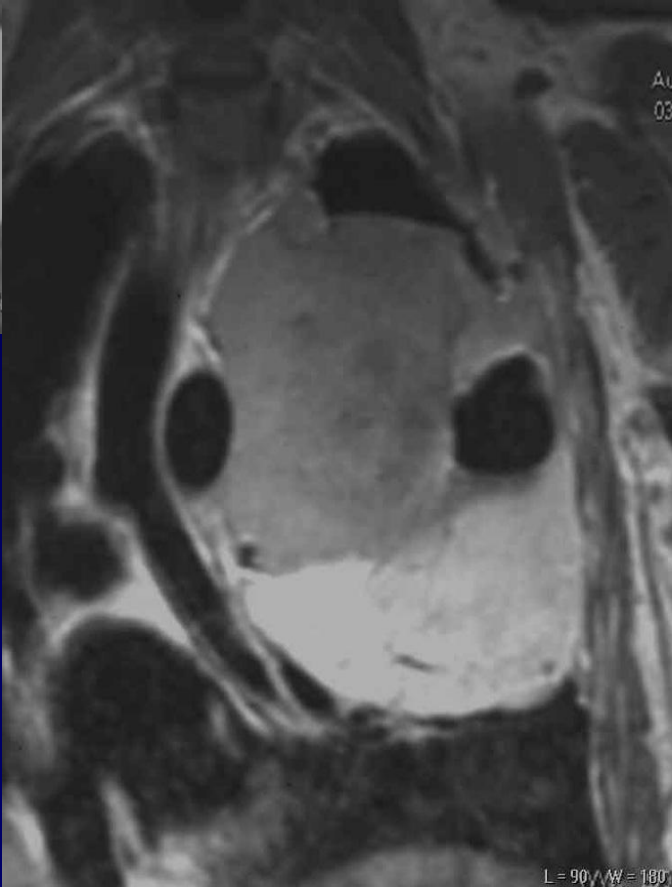
C. MEUNIER

Homme de 39 ans

Asthénie et gêne respiratoire

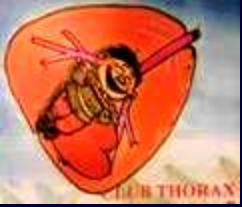







Diagnostic ?

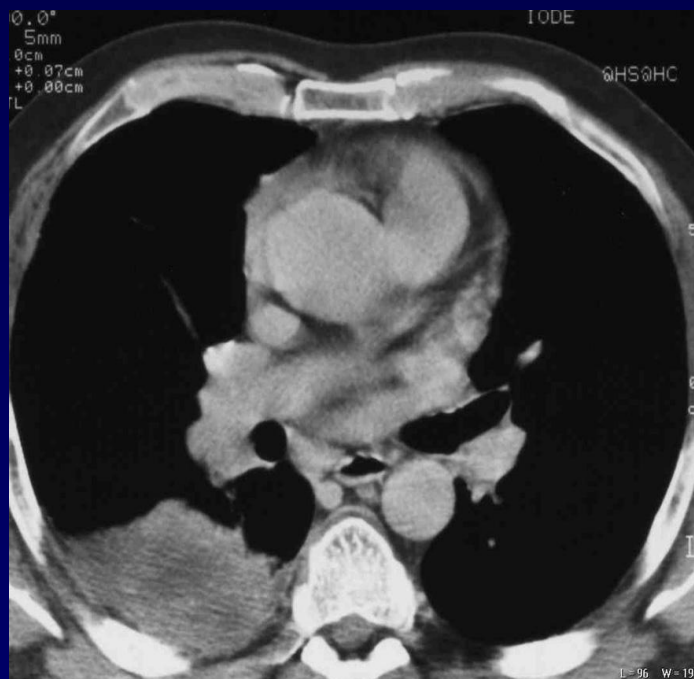
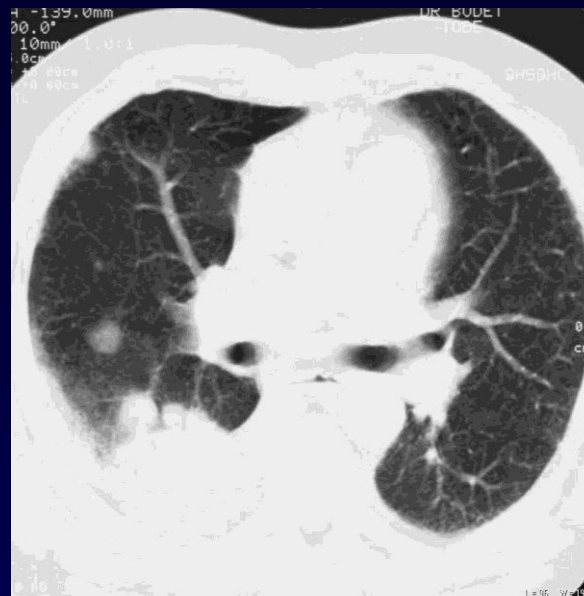
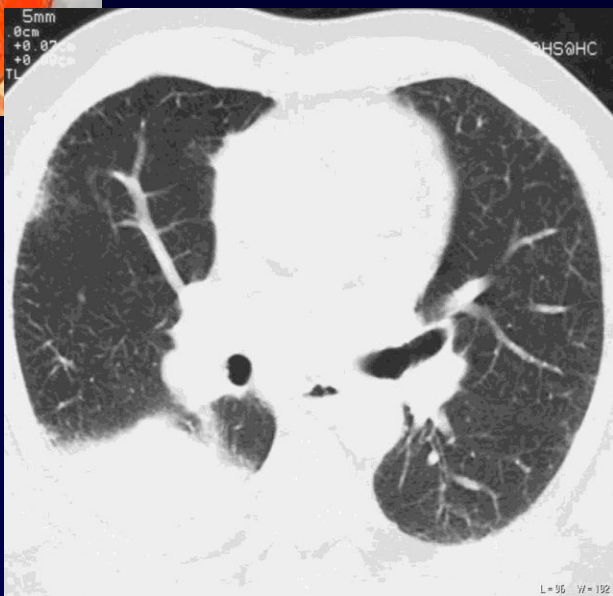
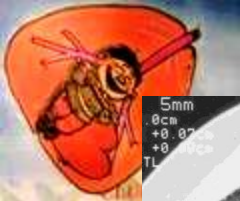


PNEUMOBLASTOME BIPHASIQUE

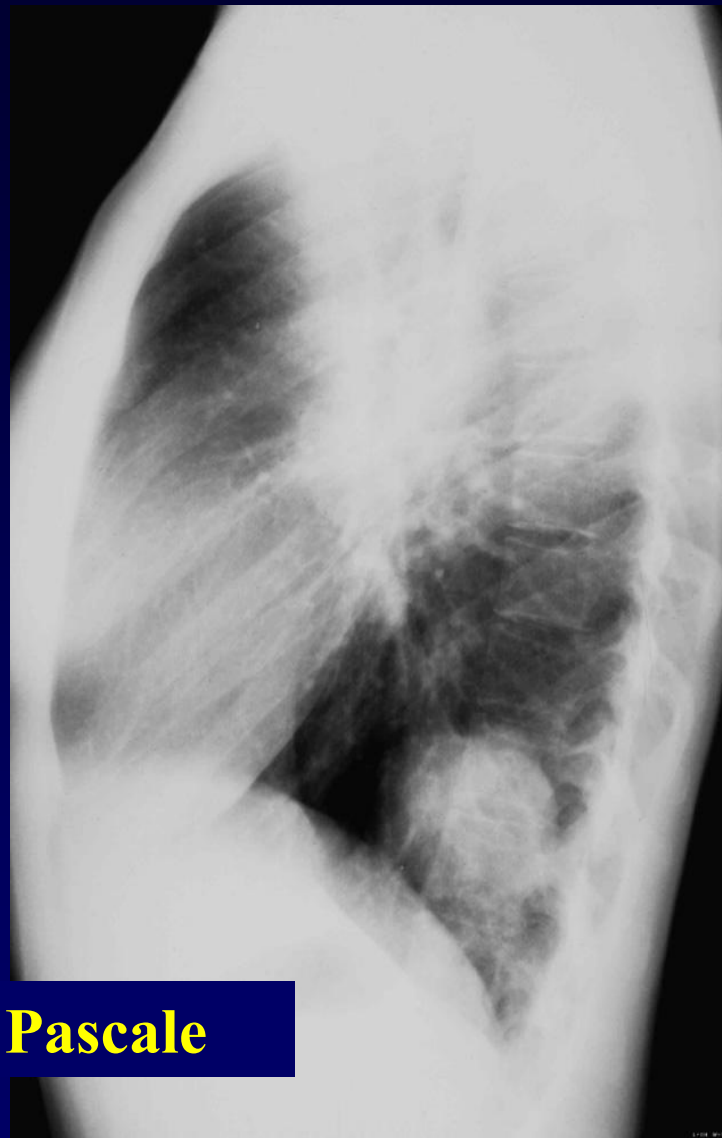
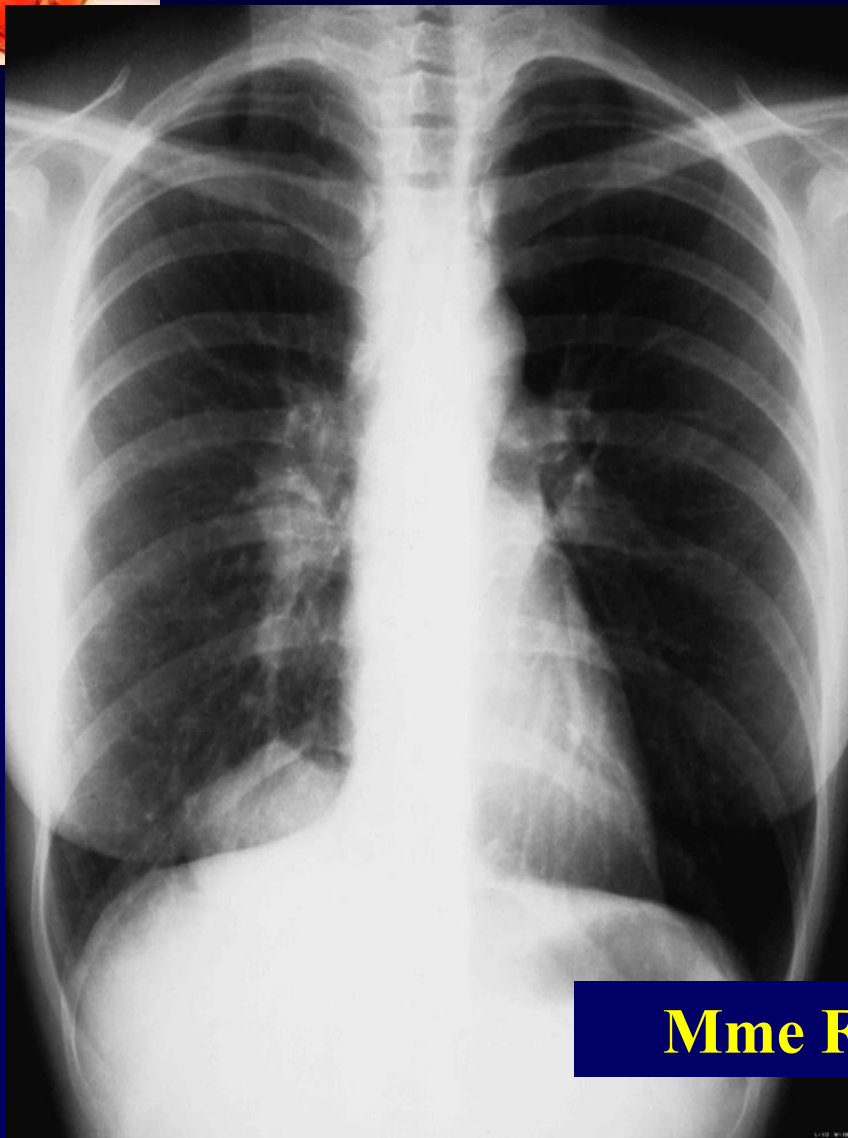(diagnostic par biopsie transpariétale)

**Les 5 dossiers suivants sont également des dossiers
de pneumoblastome recueillis par**

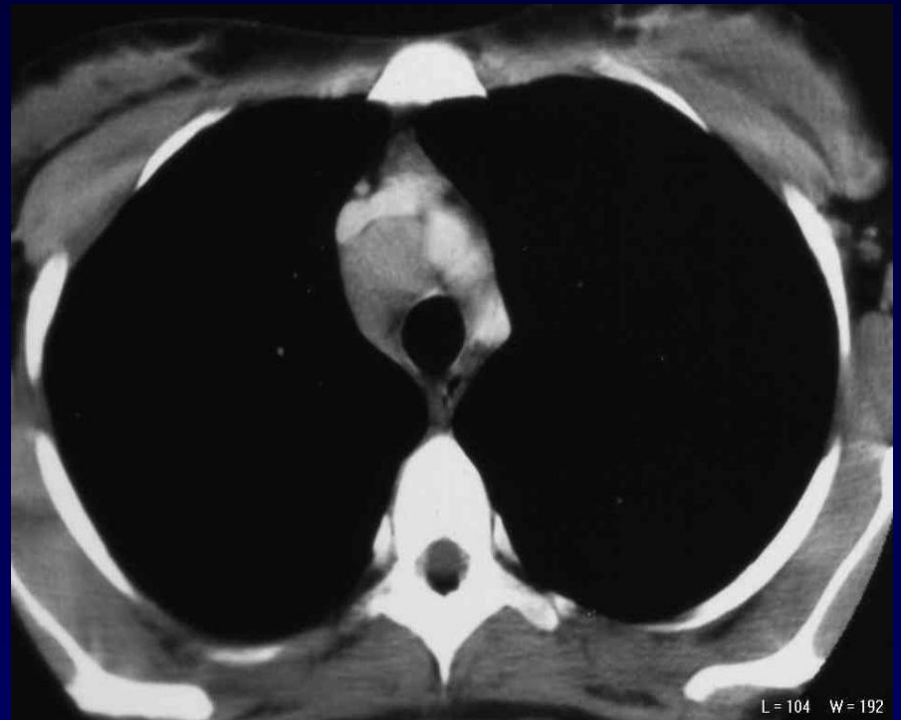
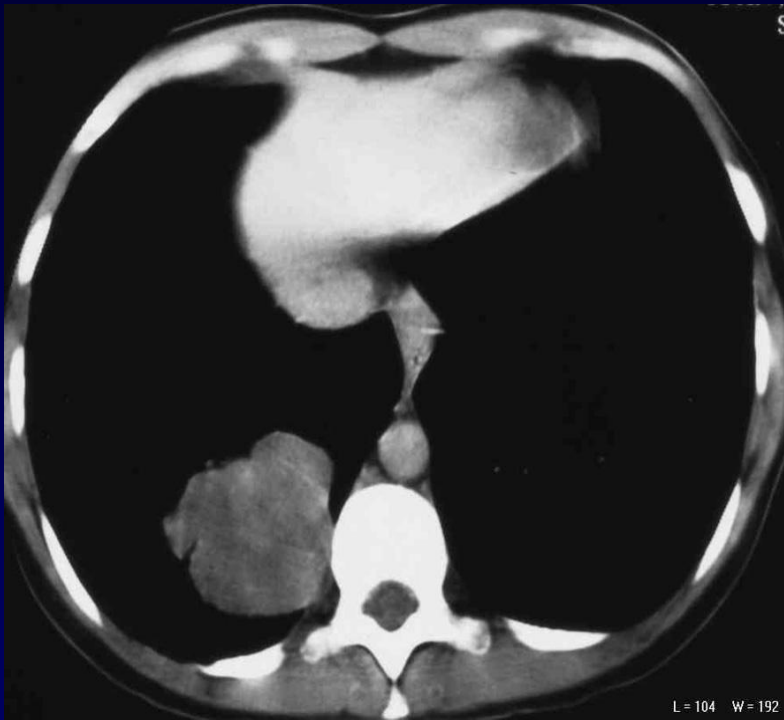
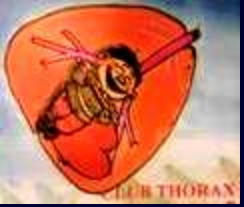Catherine MEUNIER

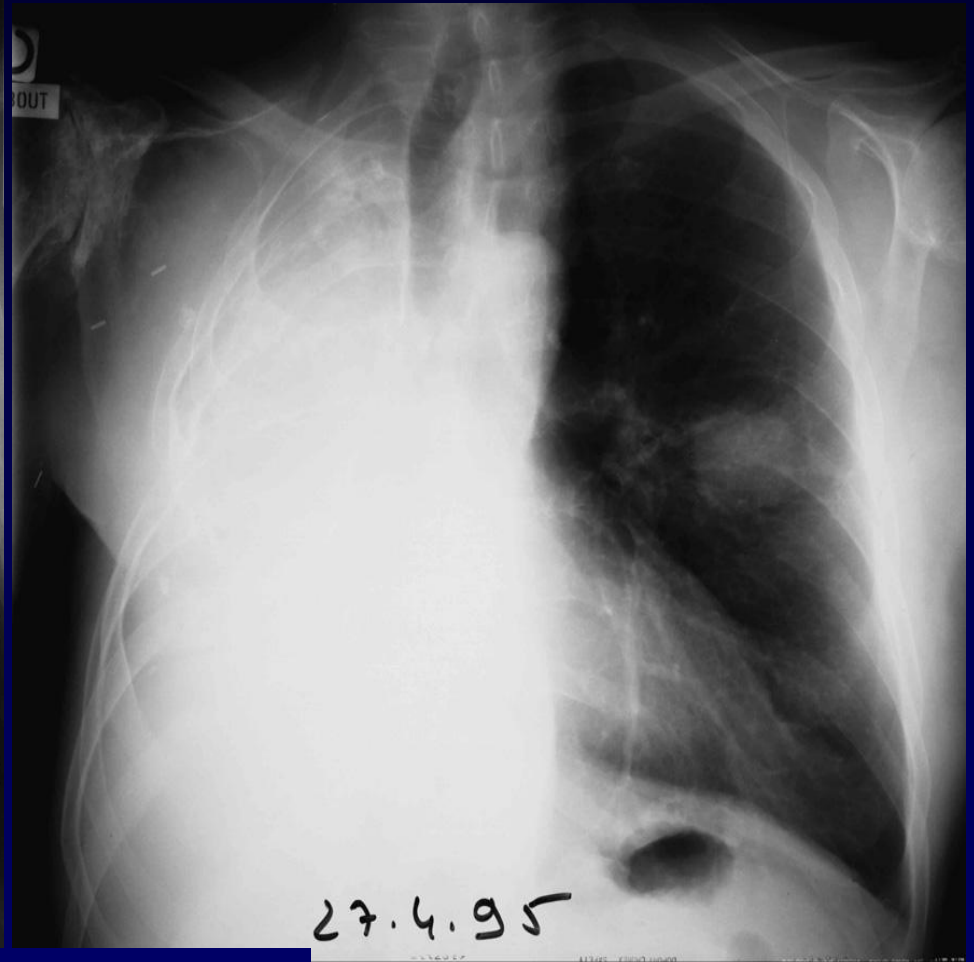
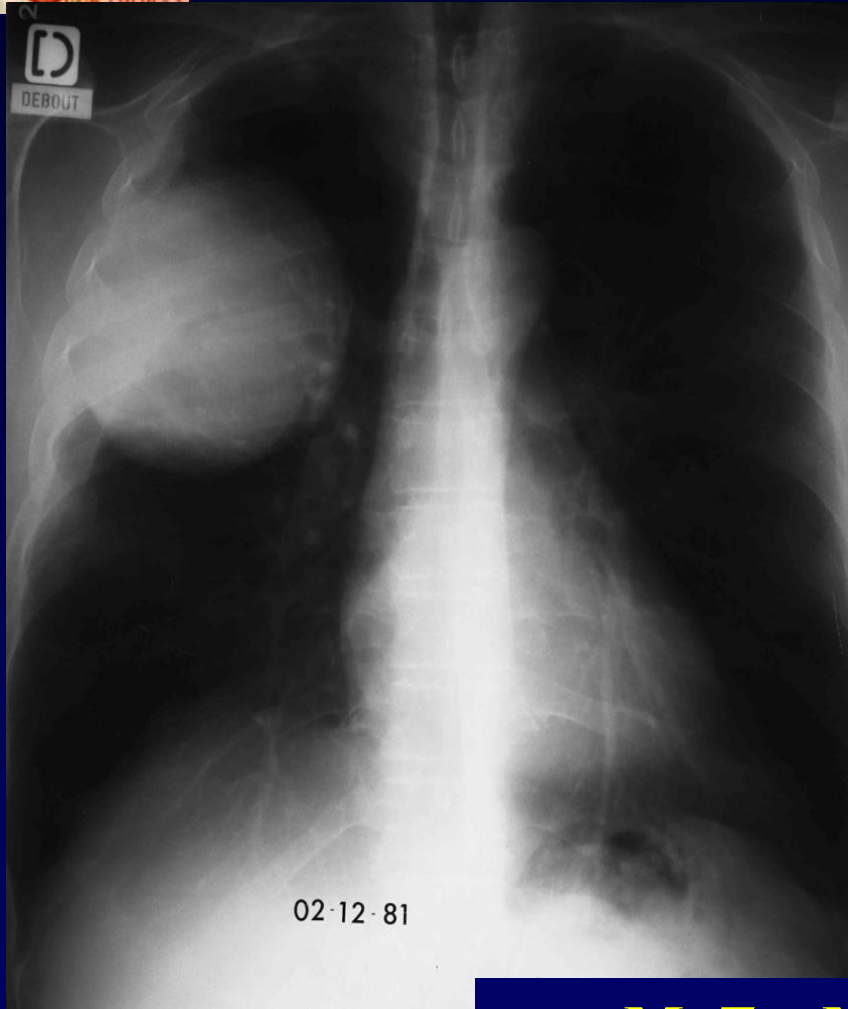

**M. L...
Gérard**

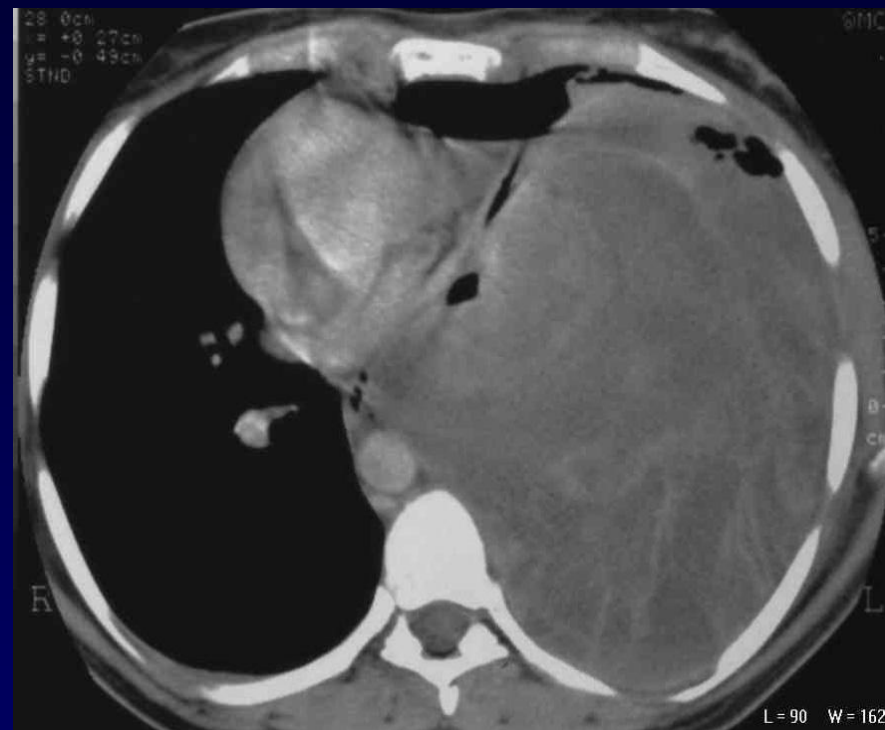
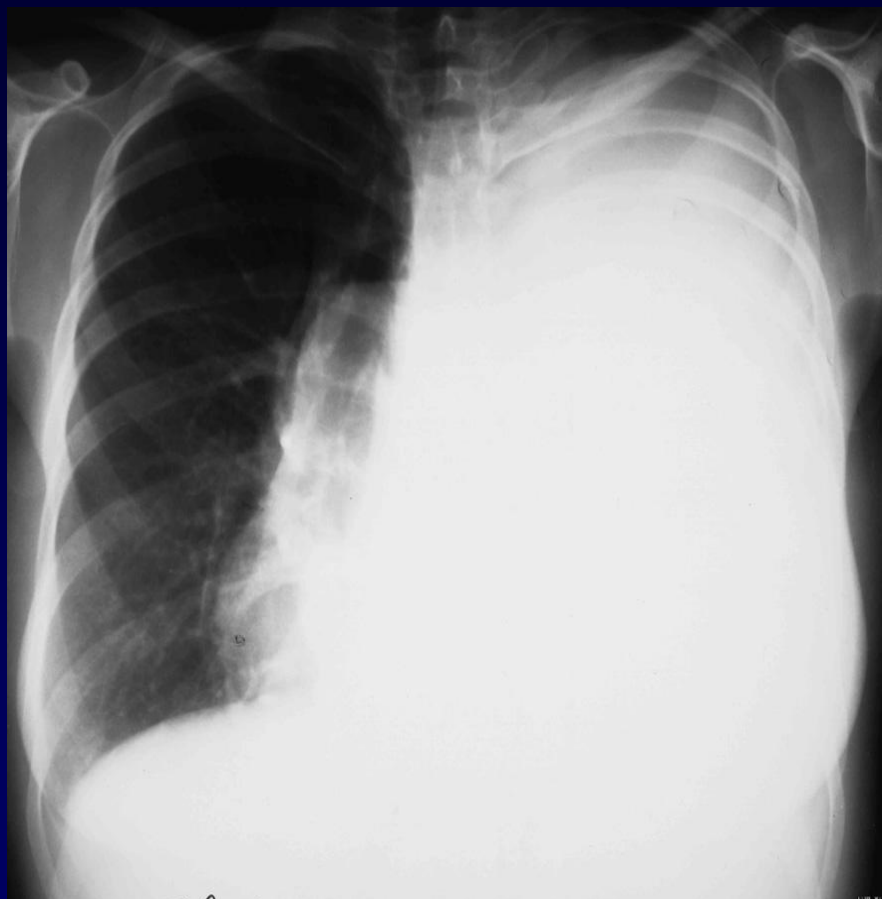
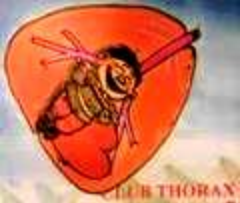
Mme F...Pascale

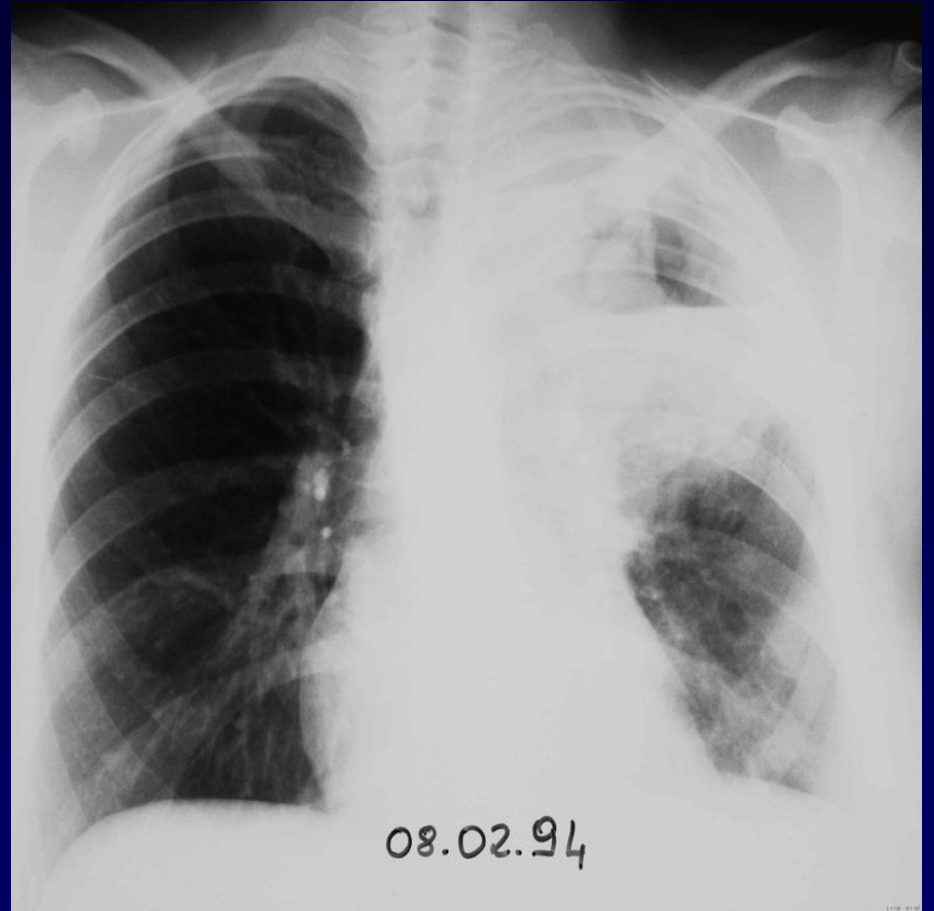
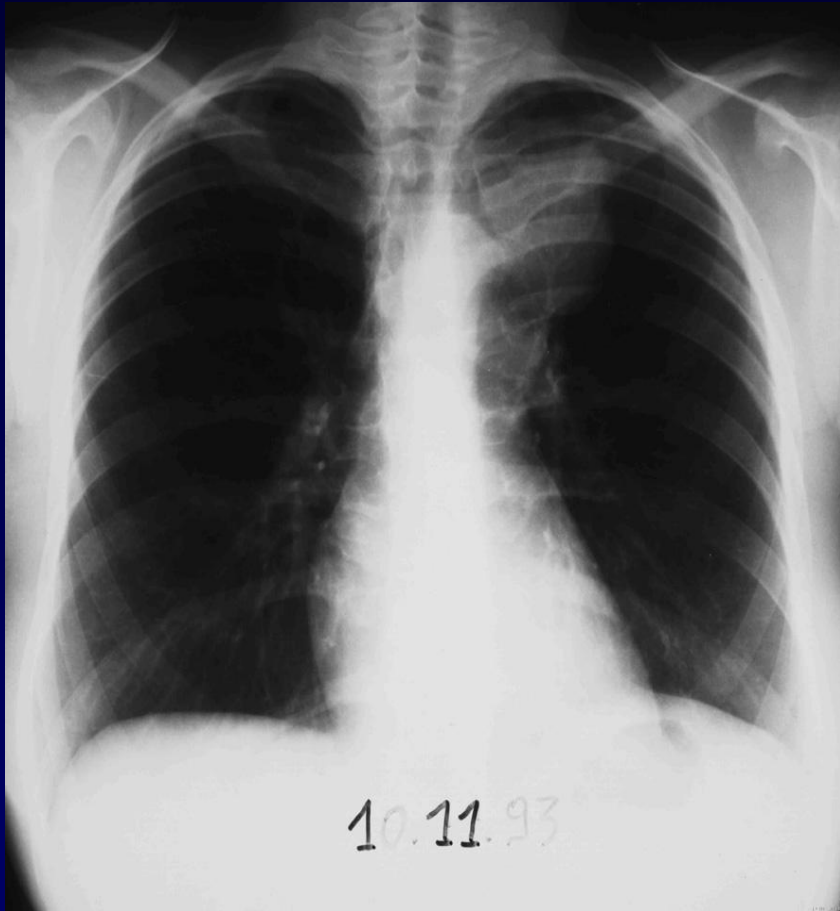



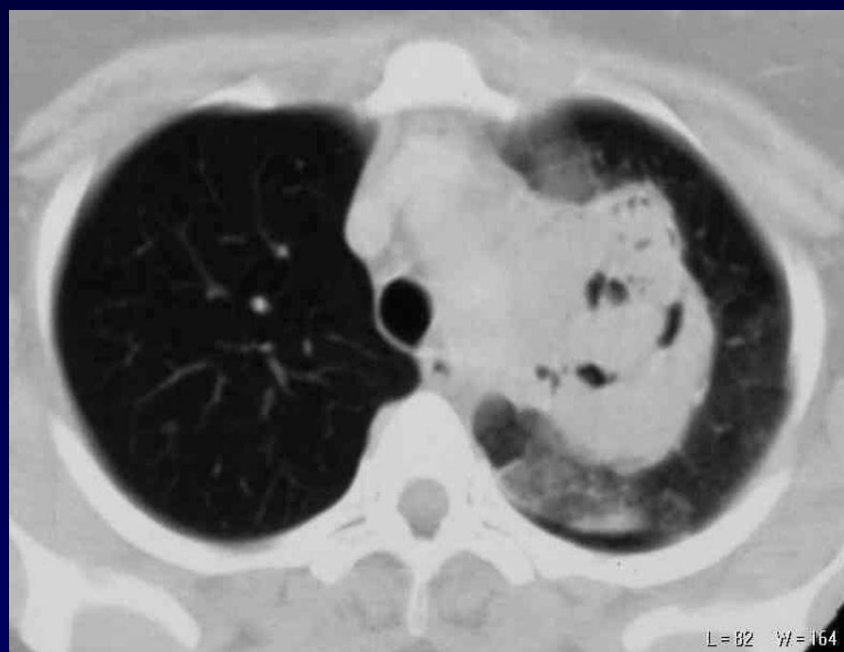
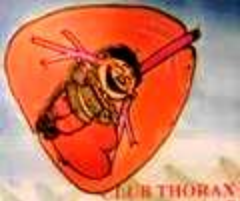M. Z...Michel



Mme F...Marie-Christine



Mme B... Nadine



Scanner et IRM de 1994

